

First report of pentastomiasis and the lung histopathological changes in Oriental Rat Snake (*Ptyas mucosa*) in Sidoarjo, East Java, Indonesia

HANI PLUMERIASTUTI^{1,*}, GARINDRA TIARA PRANASHINTA², LUCIA TRI SUWANTI³,
ANNISE PROBONINGRAT¹, KUSNOTO³

¹Division of Veterinary Pathology, Faculty of Veterinary Medicine, Universitas Airlangga. Jl. Dr. Ir. H. Soekarno, Kampus C Mulyorejo, Surabaya 60115, East Java, Indonesia. Tel.: +62-315-992785, *email: hani-p@fkh.unair.ac.id

²Magister Student, Faculty of Veterinary Medicine, Universitas Airlangga. Jl. Dr. Ir. H. Soekarno, Kampus C Mulyorejo, Surabaya 60115, East Java, Indonesia

³Division of Veterinary Parasitology, Faculty of Veterinary Medicine, Universitas Airlangga. Jl. Dr. Ir. H. Soekarno, Kampus C Mulyorejo, Surabaya 60115, East Java, Indonesia

Manuscript received: 22 January 2023. Revision accepted: 7 April 2023.

Abstract. Plumeriastuti H, Pranashinta GT, Suwanti LT, Proboningrat A, Kusnoto. 2023. First report of pentastomiasis and the lung histopathological changes in Oriental Rat Snake (*Ptyas mucosa*) in Sidoarjo, East Java, Indonesia. *Biodiversitas* 24: 2045-2051. Currently, reptiles, especially snakes, are increasingly popular as pets worldwide and are often consumed by several communities in Indonesia. This trend needs attention from a public health perspective because it can potentially cause zoonotic diseases, including parasitic disease such as pentastomiasis. This study aimed to determine: the prevalence of pentastomiasis, identify the parasite and observe the pulmonary histopathology in Oriental Rat Snakes (*Ptyas mucosa* Linnaeus 1758) collected in Tulangan, Sidoarjo, Indonesia. The methods used were calculating the prevalence of pentastomiasis, semichen-acetic carmine staining, and identifying parasites and eggs based on references as a comparison. Furthermore, histopathological preparation and hematoxylin-eosin staining were performed on the lungs infected with the parasite to observe the microscopic lesions. The results showed that 65% of the snakes had pentastomiasis, and the parasites were called *Kiricephalus pattoni* Stephens 1908. Furthermore, a microscopical examination revealed mild fibrosis in the pulmonary area due to pentastomid infestation. This study is the first reported pentastomida in *P. mucosa* in Sidoarjo, Indonesia, showing that snakes caught and commonly consumed were infected with zoonotic pentastomic.

Keywords: Colubrid snake, parasitic pneumonia, tongue worms, zoonotic parasitoses

INTRODUCTION

Exotic animals such as reptiles, especially various snakes, are now popular as pets worldwide (Okulewicz et al. 2014). However, they are also concerned with the increasing animal welfare and health issues through the animal trade in the market (Yudhana et al. 2021). Some species of snake are bred in captivity, while others are caught in the wild and sold as pets or bushmeat for consumption (Hardi et al. 2017; Yudhana et al. 2021).

Ptyas mucosa Linnaeus 1758 is a well-known snake species in Indonesia (Pranashinta et al. 2017). This type of snake, known as the Oriental Rat Snake and Indian Rat Snake, belongs to the Colubridae family which is widely distributed throughout East, South, and Southeast Asia (Auliya 2010; Muliya and Bhat 2016; Yuan et al. 2022). *P. mucosa* is a diurnal and semi-arboreal snake species that live on forest floors, agricultural fields, wet ground, and near human habitats. It feeds on frogs, rats, and other small animals (Chittora et al. 2021).

The meat of *P. mucosa* is used in the illegal trade to China (Auliya 2010). The meat and internal organs are used as fresh or frozen food, the bile and blood are used in traditional medicine, and the skin is exported to several European countries as raw materials for the leather industry (Pranashinta et al. 2017). Although illegal, most rural

communities in Indonesia trade and consume the meat and bile of *P. mucosa* for some reasons (Auliya 2010; Pranashinta et al. 2017).

Wildlife meat, however, poses a threat of transmitting infection with novel and exotic pathogens to human hosts (Hardi et al. 2017). Then new zoonotic diseases are likely to emerge consequently. For instance, Bats (Chiroptera) are important reservoirs of several emerging diseases, including Ebola Virus Disease (EVD), Severe Acute Respiratory Syndrome (SARS), and Middle East Respiratory Syndrome (MERS), as well as the current pandemic COVID-19 caused by SARS Coronavirus 2 (Irving et al. 2021). Moreover, many parasites also cause emerging zoonotic diseases, resulting in a significant public health burden, particularly in tropical countries (Alasil and Abdullah 2019).

Several parasites in confined reptiles spend a portion of their life cycle in the respiratory system. Most respiratory involvement is asymptomatic and mild, generating mostly localized inflammation except for excessive parasite loads. However, severe disease can result from high burdens or unusual host-parasite interactions, frequently worsened by secondary infections (Comolli 2021). Reptile-borne pentastomiasis is an unusual tropical disease neglected and under-researched in Asia, Africa, and South America (Sulyok et al. 2014).

Pentastomiasis is a parasitic zoonosis caused by infection with pentastomic, belonging to the subclass Pentastomida, under the phylum Arthropoda (Tongtako et al. 2013; Chittora et al. 2021; WHA 2019). Pentastomiasis is also known as tongue worms since the adult phase of the genus *Linguatula* has similarities with mammalian tongues (Paré 2008). Adult parasites are usually found in the respiratory tract of reptiles, birds, and mammals, including humans, while their larval forms are in the internal organs of insects, mammals, and amphibians (Paré 2008; Chen et al. 2010; Kelehear et al. 2014). Some zoonotic Pentastomida in snakes is *Armillifer* and *Porocephalus crotali* Humboldt 1812 (Rataj et al. 2011). Humans can be infected with pentastomic after they consume raw snake meat, have direct contact with the snake, drink water contaminated with parasitic eggs, or are contaminated through the feces (Kelehear et al. 2014; Tappe et al. 2016; Mendoza-Roldan et al. 2020).

Pentastomiasis in snakes have been reported in many countries, such as poisonous Terciopelo (*Bothrops asper* Garman 1883) in Costa Rica (Alvarado et al. 2015), Royal Python Snakes (*Python regius* Shaw 1802) in Nigeria (Ayinmode et al. 2010), Rat Snakes (*P. mucosa*) in Sri Lanka and India (Fernando and Fernando 2014; Sundar et al. 2015), wild snakes in Australia (Kelehear et al. 2014), various species of snakes in Slovenia and Pakistan (Rataj et al. 2011), Chinese Moccasin (*Agkistrodon acutus*) and Indian Python (*Python molurus* Linnaeus 1758) in China (Chen et al. 2010), and Totonacan Rattlesnake (*Crotalus totonacus* Gloyd & Kauffeld 1940) in Mexico (Tepos-Ramírez et al. 2022).

Moreover, to our best knowledge, snakes in Indonesia have no reports of pentastomic infections. Therefore, this study reported the prevalence and identified pentastomida and the pulmonary histopathological profiles in Oriental Rat Snakes (*P. mucosa*) in Sidoarjo Regency, East Java, Indonesia.

MATERIALS AND METHODS

Ethical approval

The Animal Care and Use Committee, Faculty of Veterinary Medicine, Universitas Airlangga, Surabaya, Indonesia (number 678-KE) reviewed and approved this study.

Parasite collection

The sample used comes from the Oriental Rat Snake (*P. mucosa*), which is often caught and sold for its meat and skin through collectors. The collection was conducted at a snake slaughterhouse in Tulangan District, Sidoarjo Regency, East Java Province, Indonesia. The presence of pentastomid parasites was observed in the respiratory tract of 60 slaughtered snakes. Pentastomides were taken and cleaned with distilled water, then stored in sterile plastic pots. The lungs of the snakes infected with the parasite were also isolated for histopathological preparation.

Prevalence calculation

The following formula calculated the prevalence of pentastomiasis in snake samples:

$$\text{Prevalence (\%)} = \left(\frac{\text{The number of snakes infected with pentastomids}}{\text{Total sample of snakes}} \right) \times 100\%.$$

Semichen-acetic carmine staining

The collected pentastomids were stained with the Semichen-Acetic Carmine technique (Kuhlmann 2006). Adult pentastomids were fixed on object glasses and soaked in 5% glycerin alcohol for 24 hours. Then they were soaked in 70% alcohol for five minutes. Subsequently, the object glasses with pentastomids were placed in Carmine alcohol solution (1:2) for eight hours. Next, the pentastomids were soaked in acid alcohol for 10 minutes and moved to base alcohol for 20 minutes. Furthermore, graded dehydration was carried out with 70%, 85%, and 95% alcohol for five minutes. The mounting step was done using Hung's I for 20 minutes. Finally, pentastomids were taken and placed on new clean object glasses. The pentastomids were dripped with Hung's II solutions and then covered with a cover glass.

Parasite identification

Characteristics of the head and body shape and body size of the parasite were identified based on Riley and Self (1980), Almedia et al. (2006), and Christoffersen and De Assis (2013; 2015). Identification of parasite egg size was carried out according to Keegan (1943).

The fresh parasite's length was measured from the anterior edge to the posterior end. The head was observed under a stereo microscope and documented with a Canon Digital Single-Lens Reflex (DSLR) camera. Furthermore, stained parasites were observed using a light microscope with 40-100× magnification and documented using Miconos Optilab. Some female parasites were incubated in PBS overnight at 37°C to collect the eggs. The supernatants were centrifuged at 1,500 rpm for 10 minutes, and the pellet was dripped onto a glass object and observed using a light microscope with 100× magnification. Those eggs were then measured using Miconos Optilab.

Histopathological preparations

The lungs of snakes with pentastomid infestation were fixed in 10% formalin. Then graded dehydration was carried out with serial alcohol concentrations (70%, 80%, 90%, 96%, and absolute) and clearing using xylol. Furthermore, paraffin embedding was performed to obtain a solid block of tissue. The tissue blocks were sliced (3 micrometers thick) using a microtome, mounted on an object glass, and stained using Hematoxylin and Eosin. Microscopic examination was performed using Nikon Eclipse Ci.

RESULTS AND DISCUSSIONS

The prevalence of pentastomiasis in *P. mucosa* snakes

Thirty-nine (or 65%) of the respiratory tract of 60 samples were positively infected with adult pentastomids; a

total of 204 pentastomids samples were collected (Table 1). Pentastomida was found to be strongly attached to the trachea and lungs of snakes (Figure 1). Some pentastomids even buried their heads in the lungs of snakes. The parasites of all snakes positively infected with pentastomids were found in the lungs (39 snakes), while only five (5) snakes which parasites spread to their tracheas.

This is the first study to determine the prevalence of pentastomiasis in *P. mucosa* in Sidoarjo, East Java, Indonesia. Our results showed that pentastomids were present in 39 of 60 (65%) snakes (Table 1). This finding shows the prevalence of pentastomiasis in *P. mucosa* was quite high. This study's prevalence is similar to pentastomiasis in Brazil that 8 of 15 or 53.33% of snakes were positively infected with pentastomida. The food consumed by the snakes probably caused the high prevalence in this research. The type of food is very influential on the prevalence of infection and the type of pentastomida that infected the snakes (Almeida et al. 2007). *P. mucosa* snakes usually feed on rats, frogs, toads, lizards, and even smaller non-venomous and smaller snakes (Sidik 2006). In addition, according to Esslinger (1962), rats, frogs, toads, lizards, and even non-venomous snakes can act as the intermediate hosts of pentastomida.

Identification of pentastomida

The characteristics of pentastomid found in this study can be seen in Table 2 and Figure 2. Pentastomids have a long cylindrical body with a larger head, a flat shape on the ventral, and a tapered tail or posterior. Their body was soft and whitish with a colorless cuticle, which tended to be transparent to make the internal organs visible. There were annuli throughout their body up to the posterior. There are two pairs of hooks (a total of four) around the head that attach to the host's lung tissue, and it has an ovoid-shaped mouth between the two pairs of hooks.

Both sexes, adult males and female pentastomids were found in this research (Figures 1 and 2). The number of male pentastomid was less (21 heads) than that of females (183 heads) Table 2. Table 2 also describes the size of each pentastomid. The female pentastomids had longer and larger bodies than the males (Figures 1 and 2). The length of the female bodies was 72-125 mm, with an average of 94.5 mm. Their abdominal diameter was 3.5-5 mm, averaging 4.2 mm. Furthermore, the anterior section or cephalothorax of the females was globular, with a neck separating their head and abdomen (Figure 3.A). The average length and width of the female mouths were 0.24 mm and 0.16 mm. Furthermore, the results of the microscopy examination using Carmine staining showed that the female pentastomid had two spermathecae on the anterior part. That connects directly to the uterus that contains the egg (Figures 3.C, 4.B, and 4.C). In addition, the vagina was in the posterior body and around the anus (Figure 4.B).

On the other hand, the length of the males' bodies was 17-28.5 mm, with an average of 23.75 mm. Their abdominal diameter was 1.8-2.2 mm, averaging 2 mm. The average length and width of the mouth were 0.23 and 0.14 mm, respectively. The male body was simple and straight without any curves in the neck (Figure 3.B). The genital

pore was identified in the first annulus, and there was a pair of seminal vesicles, vas deferens, and cirrus (Figure 4.D).

The eggs were oval and consisted of two layers of membrane that clearly could be distinguished. The first layer (outer membrane) was thin, while the second layer (inner membrane) was thick and yellowish. There was fluid-filled space between the first and second layers. The length of the eggs was 114-130 μm with an average of 118 μm , and the width was 108-124 μm with an average of 116 μm (Figure 3.D).

Table 1. Prevalence of pentastomiasis in *P. mucosa* based on site and the number of parasites

Sites	Positive (%)	Number of parasites
Lungs only	57% (34 of 60)	2-9 with an average of 5 Pentastomida
Trachea only	0% (0 of 60)	-
Lungs and Trachea	8% (5 of 60)	7-9 with an average of 8 Pentastomida
Total	65% (39 of 60)	204 pentastomida

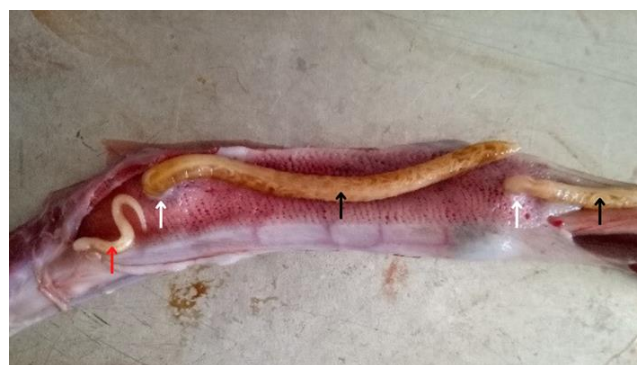

Figure 1. Pentastomid infestation in the lungs of *P. mucosa*. The white arrows show areas with raised lesions around the attachment of pentastomids to the tissue. The black arrows show female pentastomids, and the red arrow shows male pentastomids.

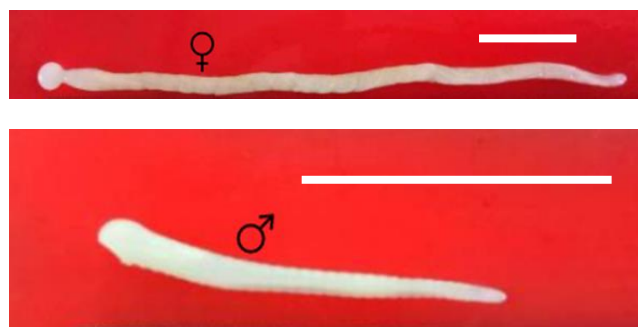


Figure 2. Differences in size between females (top) and males (below). Bar = 2 cm

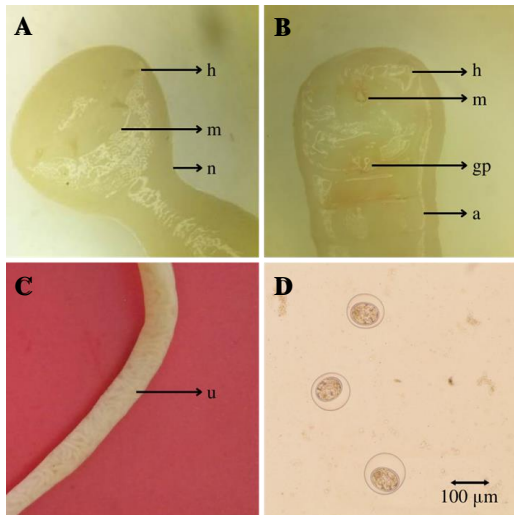


Figure 3. Pentastomida without staining. A. The anterior section of the female. B. The anterior section of the male. C. Female body. D. Pentastomid's eggs. h: hook, m: mouth, n: neck, gp: genital pore, a: first annuli, u: uterus

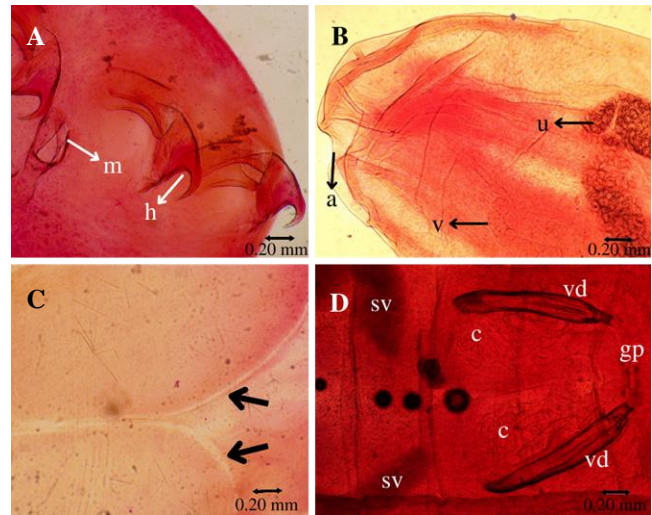


Figure 4. Carmine-stained pentastomida. A. The anterior section. B. The posterior section of the female. C. A pair of female spermatheca. D. Male reproductive organs. m: mouth, h: hook, a: anus, v: vagina, u: uterus, sv: seminal vesicle, c: cirrus, vd: vas deferens

Table 2. The characteristics of pentastomida compared with *Kirichephalus pattoni* Stephens 1908 by Riley and Self (1980) and Keegan (1943)

Parameters	The current study		British Museum collection (Riley and Self 1980)		Keegan 1943
	Females	Males	Females	Males	
Total number of parasites	183	21	17	2	-
Body length	72-125 mm (\bar{X} 94.5 mm)	17-28.5 mm (\bar{X} 23.75 mm)	83-137 mm (\bar{X} 100 mm)	28-29 mm (\bar{X} 28.5 mm)	-
Number of annuli	29-41 (\bar{X} 31.6)	28-35 (\bar{X} 31)	34-38 (\bar{X} 36.5)	31-32 (\bar{X} 31.5)	-
Diameter of cephalothorax	4-5.5 mm (\bar{X} 4.75 mm)	2-2.5 mm (\bar{X} 2 mm)	4 mm	-	-
Neck	2-3 mm (\bar{X} 2.5 mm)	-	2 mm	-	-
Diameter of abdomen	3.5-5 mm (\bar{X} 4.2 mm)	1.8-2.2 mm (\bar{X} 2 mm)	4 mm	-	-
Hook parameter:					
AC	0.23-0.55 mm	0.22-0.35 mm	-	-	-
CB	0.37-0.69 mm	0.29-0.35 mm	-	-	-
AD	0.47-0.88 mm	0.29-0.45 mm	-	-	-
Mouth:					
Length	0.16-29 mm	0.14-0.38 mm	-	-	-
Width	0.12-0.24 mm	0.12-0.18 mm	-	-	-
Egg:					
Length	114-130 μ m (\bar{X} 118 μ m)	-	-	-	125-154 μ m (\bar{X} 133 μ m)
Width	108-124 μ m (\bar{X} 116 μ m)	-	-	-	106-143 μ m (\bar{X} 123 μ m)

Pentastomida was mostly found in the lungs, and the parasites also spread to the trachea in five snakes. This finding was similar to research by Riley and Self (1980) that revealed that adult *K. pattoni* (one of the pentastomida species) were only found in the lungs of *P. mucosa* snakes. In our observation, pentastomids that spread to the trachea were females. According to Sundar et al. (2015), the adult pentastomids with mature eggs are expelled from the trachea and eliminated from the definitive host by oral

expulsion or may also be swallowed. That results in shed eggs in the feces, which another intermediate mammal host will ingest to continue their life cycles.

The number of male pentastomids was fewer than the number of female ones. This case was also experienced by John and Nadakal (1988) and Riley and Self (1980), who only found a few males compared the female. This study result follows Almeida et al. (2006), whose number of pentastomids and their species is unknown in biology.

The taxonomy of pentastomida is still controversial. Moreover, it has been known through molecular data that pentastomida are closely related to crustaceans and belong to the class Maxillopoda, sub-phylum Crustacea, and the phylum Arthropoda (Paré 2008). Based on the egg size (Almeida et al. 2007); the female head form that globular with a neck separating the head from its body (Paré 2008); and the size of the body length, the number of the annuli, the diameter of the cephalothorax, neck, abdominal diameter, head, and body shape (Riley and Self 1979; Riley and Self 1980); pentastomida was classified as *K. pattoni*. *K. pattoni* can be classified as Porocephalida (Paré 2008). In addition, according to Christoffersen and De Assis (2013; 2015), pentastomid in *P. mucosa* snakes are classified into *K. pattoni*.

K. pattoni has a long annulated body, a tapered tail, an anal canal, two pairs of hooks or four hooks on its head, and a small ovoid-shaped mouth (Riley and Self 1979). The female *K. pattoni* has a larger body than the male one (Paré 2008). Female *K. pattoni* also has a spiral body with a larger head than its body, and a curve of the neck, whereas male one has a straight body without a curve on the neck (Riley and Self 1979; Riley and Self 1980; John and Nadakal 1988; Almeida et al. 2007). The spiral body in females is likely to facilitate their movement into the lung tissue of the definitive hosts (John and Nadakal 1988).

The egg morphology is similar to the eggs of *P. crotali* described by Sundar et al. (2015). These eggs were composed of two-layer membranes, of which the outer one was thin and the inner membrane thick, and there was a fluid-filled space between those two membranes. But the average diameter of the eggs measured in this investigation is smaller (118x116 µm) than the eggs of *P. crotali* (144 µm), as described by Sundar et al. (2015).

Histopathological changes in the lungs of *P. mucosa*

Squamates typically have two lungs; however, the left lung in most snakes is greatly reduced, never exceeding 85% of the right lung's size or absence (Funk and Bogan 2019). The right lung usually runs from near the heart to the cranial to the right kidney (Funk and Bogan 2019). The cranial portion of a lung is vascularized and functions primarily as a gas exchanger (vascular lung), whereas the caudal primarily functions as an air sac (saccular lung). The vascular lung's wall comprises honeycombed units called faveoli, allowing gas exchange (Funk and Bogan 2019). The faveoli in the snake lung parenchyma are lined microscopically by squamous epithelial cells (type I cells). In addition to a lesser degree, by cuboidal epithelial cells (type II) (Jacobson et al. 2021).

In this study, a nymphal stage of the parasite was found in the pulmonary tissue infected with pentastomida. The parasite is surrounded by some connective tissue (Figure 5). Finding the stages of the nymph in the snake's histological lung and the parasite's stages in the macroscopic lung organ means that the *P. mucosa* snake may act as an intermediate and final host of *K. pattoni*. Within the lung cavities of the definitive host, the nymphs develop into adults (Sundar et al. 2015). In this study, pentastomida infection in the lungs only caused a mild

histological reaction in the form of fibrosis in the area around the parasite.

Pentastomida has an indirect life cycle that typically utilizes vertebrate hosts. Consequently, these species rely on reptiles as their definitive host. The adults are usually found in their lungs (Wellehan and Walden 2019). Pentastomida parasites migrate extensively through the visceral before settling in the lungs and, less typically, the trachea and nasal passageways. Pentastomida can produce localized lesions, while molting can elicit antigenic reactions. Adults feed on lung tissue fluids and pass embryonated eggs, which are coughed up through the oral cavity, swallowed, and passed in the feces (Comolli and Divers 2021). In squamates, the pulmonary lumen is large, and the tracheal diameter may be smaller than that of the pentastomids. That poses a risk of respiratory obstruction by the adult pentastomids. However, the greatest pathological changes are seen in the intermediate host, where they may become embedded in tissues (Wellehan and Walden 2019).

Pentastomiasis in reptiles, especially snakes, occurs subclinically. Although the infection is large, death is usually associated with secondary septicemia and pneumonia (Tappe and Büttner 2009). Because pentastomids attach to the lung tissue, they can cause perforation, hemorrhaging, and serious inflammation in the host (Fernando and Fernando 2014). In a Common Garter Snake (*Thamnophis sirtalis* Linnaeus 1758), lung lesions were associated with one of the pentastomida species, *Kiricephalus coarctatus* Diesing 1850, where the embedded parasite had gotten into the hypaxial muscle. Infections with *Armillifer armillatus* Wyman 1845 have also been linked to parasitic pneumonia in gaboon vipers. Pentastomids occluding the trachea have been implicated in snake deaths. Bacterial infections could develop due to lung damage. For example, there are four out of nine *Boa constrictors* with pulmonary damage from *Porocephalus dominicana* Riley & Walters 1980 infection perished due to bacteremia and pericarditis (Walden et al. 2021).

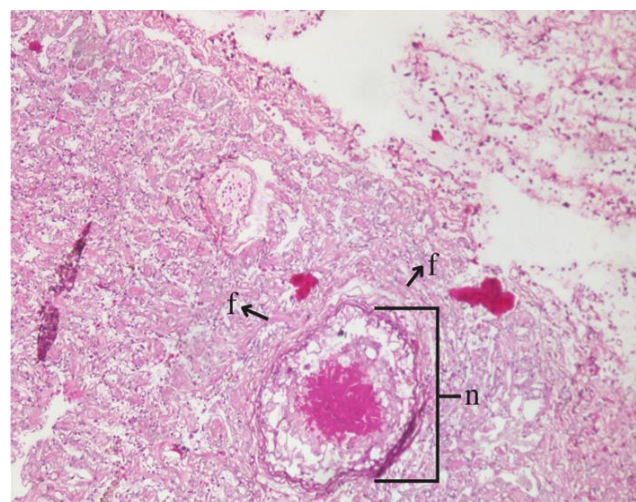


Figure 5. Histological microscopic picture of nymph-infected pulmo from pentastomida showed the presence of fibroblast around the area of infection. f: fibroblast, n: the body of the nymph stage pentastomida

Bigger implications regarding possible impacts on human health may be anticipated based on the histopathological changes found in this study. Humans are the final hosts of pentastomic, which can be contracted from improperly cooked meat from infected snakes or drinking water contaminated with pentastomida eggs. In addition, humans can get the infection when handling and harvesting snakeskin or having direct contact with the mouth of a pet snake (Latif et al. 2016). The pathological consequences of the clinical symptoms experienced by infected humans may be the same or even more severe. That depends on the number of parasite eggs ingested, the duration from the larvae migrating to various organs to maturity and reproduction, and how severe the parasite infestation is in the human viscera.

Personal hygiene measures are required to prevent human infections. For example, avoid drinking river water directly or boiling the water before drinking. In addition, authorities should provide health education to warn people about eating undercooked snake meat, the possibility of transmission after handling snakes, and avoiding contact with snake excretions.

In conclusion the prevalence of pentastomiasis in slaughtered *P. mucosa* in Sidoarjo was 65% (39 of 60 snakes). The pentastomids that infect these snakes are classified as *K. pattoni*. The pulmonary histological findings only show a light reaction in the form of mild fibrosis.

ACKNOWLEDGEMENTS

We sincerely thank all snake collectors who participated in this research.

REFERENCES

- Alasil SM, Abdullah KA. 2019. An epidemiological review on emerging and re-emerging parasitic infectious diseases in Malaysia. *Open Microbiol J* 13: 112-120. DOI: 10.2174/1874285801913010112.
- Almeida WO, Brito SV, Ferreira FS, Christoffersen ML. 2006. First record of *Cephalobaena tetrapoda* (pentastomida: cephalobaenidae) as a parasite on *Liophis lineatus* (ophidia: colubridae) in Northeast Brazil. *Brazilian J Biol* 66 (2A): 559-564. DOI: 10.1590/s1519-69842006000300023.
- Almeida WO, Vasconcellos A, Lopes SG, Freire EMX. 2007. Prevalence and intensity of pentastomid infection in two species of snakes from northeastern Brazil. *Brazilian J Biol* 67 (4): 759-763. DOI: 10.1590/s1519-69842007000400025.
- Alvarado G, Sánchez-Monge A. 2015. First record of *Porocephalus cf. clavatus* (Pentastomida: Porocephalida) as a parasite on *Bothrops asper* (Squamata: Viperidae) in Costa Rica. *Brazilian J Biol* 75 (4): 854-858. DOI: 10.1590/1519-6984.01414.
- Auliya M. 2010. Conservation status and impact of trade on the Oriental rat snake *Ptyas mucosa* in Java, Indonesia. *TRAFFIC Southeast Asia, Petaling Jaya, Selangor, Malaysia*.
- Ayinmode AB, Adedokun AO, Aina A, Taiwo V. 2010. The zoonotic implications of pentastomiasis in the Royal Python (*Python regius*). *Ghana Med J* 44 (3): 115-118. DOI: 10.4314/2Fgmj.v44i3.68895.
- Chen S, Liu Q, Zhang Y, Chen J, Li H, Chen Y, Steinmaan P, Zhou X. 2010. Multi-host model-based identification of *Armillifer agkistrodontis* (Pentastomida), a new zoonotic parasite from China. *PLoS Negl Trop Dis* 4: e647. DOI: 10.1371/journal.pntd.0000647.
- Chittora RK, Jadhav AS, Upreti NC, Vikas G, Baviskar B. 2021. Occurrence of *Porocephalus crotali* in lung tissue of an Indian rat snake (*Ptyas mucosa*): A case report. *J Entomol Zool Stud* 9 (1): 1478-1480. DOI: 10.22271/j.ent.
- Christoffersen ML, De Assis JE. 2013. A systematic monograph of the Recent Pentastomida, with a compilation of their hosts. *Zoologische Mededelingen* 87 (1): 1-206.
- Christoffersen ML, De Assis JE. 2015. Pentastomida. *Revista IDE@-SEA, Ibero Diversidad Entomológica@ ccesible B*. 98: 1-10.
- Comolli JR, Divers SJ. 2021. Respiratory diseases of snakes. *Vet Clin N Am: Exotic Animal Practice* 24 (2): 321-340. DOI: 10.1016/j.cvex.2021.01.003.
- Esslinger JH. 1962. Development of *Porocephalus crotali* (Humboldt, 1808) (Pentastomida) in experimental intermediate hosts. *J Parasitol* 48 (3): 452-456. DOI: 10.2307/3275214.
- Fernando T, Fernando V. 2014. A pentastome (*Armillifer moniliformis*) parasitizing a common rat-snake. *TAPROBANICA: J Asian Biodivers* 6 (1): 47-48. DOI: 10.4038/taprov.v6i1.7085.
- Funk RS, Bogan JE. 2019. Snake Taxonomy, Anatomy, and Physiology. In *Mader's Reptile and Amphibian Medicine and Surgery*. Elsevier, Philadelphia.
- Hardi R, Babocsay G, Tappe D, Sulyok M, Bodó I, Rózsa L. 2017. Armilifer-infected snakes sold at Congolese bushmeat markets represent and emerging zoonotic threat. *EcoHealth* 14: 743-749. DOI: 10.1007/s10393-017-1274-5.
- Irving AT, Ahn M, Goh G, Anderson DE, Wang L. 2021. Lessons from the host defences of bats, a unique viral reservoir. *Nature* 589: 363-370. DOI: 10.1038/s41586-020-03128-0.
- Jacobson ER, Lillywhite HB, Blackburn DG. 2021. Overview of Biology, Anatomy, and Histology of Reptiles. In *Infectious Diseases and Pathology of Reptiles*. Color Atlas and Text. Taylor & Francis Group, Boca Raton.
- John MV, Nadakal AM. 1988. Juvenile precocity and maintenance of juvenile features in the males of the pentastome *Kiricephalus pattoni* (Stephens, 1908) Sambon, 1922. *Intl J Invertebr Reprod Dev* 14 (2-3): 295-298. DOI: 10.1080/01688170.1988.10510387.
- Keegan HL. 1943. Observations on the Pentastomid, *Kiricephalus coarctatus* (Diesing) Sambon 1910. *Trans Am Microsc Soc* 62 (2): 194-199. DOI: 10.2307/3222921.
- Kelehear C, Spratt DM, O'Meally D, Shine R. 2014. Pentastomids of wild snakes in the Australian tropics. *Intl J Parasitol Parasites Wildl* 3: 20-31. DOI: 10.1016/j.ijppaw.2013.12.003.
- Kuhlmann WF. 2006. Preservation, Staining, and Mounting Parasite Speciment. <http://www.facstaff.unca.com>. 8p.
- Latif BMA, Muslim A, Chin HC. 2016. Human and animal pentastomiasis in malaysia: review. *J Trop Life Sci* 6 (2): 131-135. DOI: 10.11594/jtls.06.02.12.
- Mendoza-Roldan JA, Modry D, Otranto D. 2020. Zoonotic parasites of reptiles: A crawling threat. *Trends Parasitol* 36 (8): 677-687. DOI: 10.1016/j.pt.2020.04.014.
- Muliya SK, Bhat MN. 2016. Hematology and serum biochemistry of Indian spectacled cobra (*Naja naja*) and Indian rat snake (*Ptyas mucosa*). *Vet World* 9: 909-914. DOI: 10.14202/vetworld.2016.909-914.
- Okulewicz, Kazmierczak M, Zdrzalik K. 2014. Endoparasites of exotic snakes (Ophidia). *Helminthologia* 51: 31-36. DOI: 10.2478/s11687-014-0205-z.
- Paré JA. 2008. An overview of pentastomiasis in reptiles and other vertebrates. *J Exotic Pet Med* 7 (4): 285-294. DOI: 10.1053/j.jepm.2008.07.005.
- Pranashinta GT, Suwanti LT, Koesdarto S, Poetranto ED. 2017. Spirometra in *Ptyas mucosus* snake in Sidoarjo, Indonesia. *Vet Med Intl Conf KnE Life Sci* 34-40. DOI: 10.18502/kl.v3i6.1104.
- Rataj AV, Lindtner-Knific R, Vlahović K, Mavri U, Dovč A. 2011. Parasites in pet reptiles. *Acta Veterinaria Scandinavica* 53: 33. DOI: 10.1186/1751-0147-53-33.
- Riley J, Self JT. 1979. On the systematics of the pentastomid genus *Porocephalus* (Humboldt, 1811) with descriptions of two new species. *Syst Parasitol* 1: 25-42. DOI: 10.1007/BF00009772.
- Riley J, Self JT. 1980. On the systematics and life-cycle of the pentastomid genus *Kiricephalus* Sambon, 1922 with descriptions of three new species. *Syst Parasitol* 1 (2): 127-140. DOI: 10.1007/BF00009859.
- Sidik I. 2006. Analisis isi perut dan ukuran tubuh ular jali (*Ptyas mucosus*). *Zoo Indonesia Jurnal Fauna Tropika* 15: 121-127. DOI: 10.52508/zi.v15i2.113. [Indonesian]

- Sulyok M, Rózsa L, Bodó I, Tappe D, Hardi R. 2014. Ocular pentastomiasis in the Democratic Republic of the Congo. *PLOS Negl Trop Dis* 8 (7): e3041. DOI: 10.1371/journal.pntd.0003041.
- Sundar STB, Palanivelrajan M, Kavitha KT, Azhahianambi P, Jeyathilakan N, Gomathinayagam S, Raman M, Harikrishnan TJ, Latha BR. 2015. Occurrence of the pentastomid *Porocephalus crotali* (Humboldt, 1811) in an Indian rat snake (*Ptyas mucosus*): A case report. *J Parasit Dis* 39 (3): 401-404. DOI: 10.1007/s12639-013-0336-z.
- Tappe D, Büttner DW. 2009. Diagnosis of human visceral pentastomiasis. *PLOS Negl Trop Dis* 3: e320. DOI: 10.1371/journal.pntd.0000320.
- Tappe D, Sulyok M, Riu T, Rózsa L, Bodó I, Schoen C, Muntau B, Babocsay G, Hardi R. 2016. Co-infections in visceral pentastomiasis, Democratic Republic of the Congo. *Emerg Infect Dis* 22 (8): 1333-1339. DOI: 10.3201%2F151895.
- Tepos-Ramírez M, Mena DIH, Lagunas O, Ugalde Sánchez V, Valencia-García R-D, Hernández-Camacho N. 2022. Endoparasitismo y fibrosis en *crotalus totonacus* (viperidae) de la sierra gorda de querétaro, méxico. *Revista Latinoamericana De Herpetología* 5 (2): 33-37. DOI: 10.22201/fc.25942158e.2022.2.365.
- Tongtako W, Chandrawathani P, Premalatha B, Shafarin MS, Azizah D. 2013. Pentastomid (*Armilifer moniliformis*) infection in Malaysian Blood Python (*Python curtus*). *Malays J Vet Res* 4 (1): 51-54.
- Walden HDS, Greiner EC, Jacobson ER. 2021. Parasites and Parasitic Diseases of Reptiles. *Infectious Diseases and Pathology of Reptiles*. CRC Press, Boca Raton, Florida.
- Wellehan JFX, Walden HDS. 2019. Parasitology (Including Hemoparasites). *Mader's Reptile and Amphibian Medicine and Surgery*. Elsevier. DOI: 10.1016/B978-0-323-48253-0.00032-5.
- WHA [Wildlife Health Australia]. 2019. Pentastomiasis in Australian Reptiles. <https://wildlifehealthaustralia.com.au>
- Yuan FL, Yeung CT, Prigge T, Dufour PC, Sung Y, Dingle C, Bonebrake TC. 2022. Conservation and cultural intersections within Hong Kong's snake soup industry. *Oryx* 57 (1): 40-47. DOI: 10.1017/S0030605321001630.
- Yudhana A, Praja R.N, Supriyanto A. 2021. Acanthocephaliasis and sparganosis occurrence in an Asian vine snake (*Ahaetulla prasina*): A perspective of neglected zoonotic disease. *IOP Conf Ser Earth Environ Sci* 755: 012003. DOI: 10.1088/1755-1315/755/1/012003.