BIODIVERSITAS
Volume 26, Number 8, August 2025
Pages: 4146-4156

ISSN: 1412-033X
E-ISSN: 2085-4722
DOI: 10.13057/biodiv/d260842

Endoparasite diversity and zoonotic risk in wild-caught Javan spitting cobra (*Naja sputatrix*) from Indonesia

RYANKA EDILA[1], MUSTOFA HELMI EFFENDI[2,6,♥], LUCIA TRI SUWANTI[3,5], HYUCK-KEUN KWON[4], JOHN YEW HUAT TANG[6], SAIFUR REHMAN[7]

[1]Doctoral Program of Veterinary Science, Faculty of Veterinary Medicine, Universitas Airlangga. Jl. Mulyorejo, Kampus C Unair, Surabaya 60115, East Java, Indonesia
[2]Division of Veterinary Public Health, Faculty of Veterinary Medicine, Universitas Airlangga. Jl. Mulyorejo, Kampus C Unair, Surabaya 60115, East Java, Indonesia. Tel.: +62-315-992785, Fax.: +62-315-993015, ♥email: mustofa-h-e@fkh.unair.ac.id
[3]Division of Veterinary Parasitology, Faculty of Veterinary Medicine, Universitas Airlangga. Jl. Mulyorejo, Kampus C Unair, Surabaya 60115, East Java, Indonesia
[4]College of Veterinary Medicine, Konkuk University. 120 Neungdong-ro, Gwangjin-gu, Seoul 05029, Republic of Korea
[5]Institute of Tropical Diseases, Universitas Airlangga. Jl. Mulyorejo, Kampus C Unair, Surabaya 60115, East Java, Indonesia
[6]School of Food Industry, Faculty of Bioresources, and Food Industry, Universiti Sultan Zainal Abidin. 22200 Besut, Terengganu, Malaysia
[7]Department of Pathobiology, Faculty of Veterinary and Animal Sciences, Gomal University. Dera Ismail Khan, Khyber Pakhtunkhwa, Pakistan

Manuscript received: 30 April 2025. Revision accepted: 27 August 2025.

Abstract. *Edila R, Effendi MH, Suwanti LT, Kwon H-K, Tang JYH, Rehman S. 2025. Endoparasite diversity and zoonotic risk in wild-caught Javan spitting cobra* (Naja sputatrix) *from Indonesia. Biodiversitas 26: 4146-4156.* The Javan spitting cobra (*Naja sputatrix*) is widely used in Indonesia for food and traditional medicine, creating potential zoonotic risks from parasitic infections. This study aimed to assess the diversity and prevalence of endoparasites in wild-caught *N. sputatrix* purchased from local sellers in Sidoarjo, East Java, Indonesia. Fifty-one snakes were examined through necropsy, coprological, and blood smear analyses. Parasitic infection was detected in 82.3% (42/51) of snakes, with mixed infections predominating across all age groups. A total of ten parasite taxa were identified, including nematodes (*Capillaria*, *Kalicephalus*, *Strongyloides*, *Ophidascaris*), cestodes (*Spirometra*), acanthocephalans (*Sphaerechinorhynchus*), pentastomids (*Porocephalus*), intestinal protozoa (*Balantidium*, *Eimeria*), and a hemoparasite (*Hepatozoon*). Notably, zoonotic species such as *Spirometra* spp. (54.9%), *Porocephalus* spp. (11.76%), and *Ophidascaris* spp. (7.84%) were prevalent, underscoring public health threats associated with snake consumption and handling. This is the first comprehensive parasitological survey of *N. sputatrix* in Indonesia and the first host record of *Porocephalus* in this species. Findings highlight the ecological role of cobras as reservoirs of zoonotic parasites and emphasize the need for One Health surveillance to mitigate cross-species transmission risks. The study also contributes baseline data for wildlife trade monitoring, biodiversity conservation, and public health policy related to human-snake interactions in Southeast Asia.

Keywords: Helminth, infectious diseases, one health, protozoa, snake parasite

INTRODUCTION

Snakes have long played an important role in the cultural, medicinal, and culinary traditions of various societies, particularly in Southeast Asia. In Indonesia, snakes are commonly consumed as exotic delicacies, prepared in the form of satay, grilled meat, or soup, and also used in traditional medicine and rituals (Utama et al. 2024). In traditional belief systems, snake meat is widely believed to alleviate or cure a variety of ailments, including skin disorders, respiratory and digestive ailments, musculoskeletal problems, as well as tumors and cancers (Mukherjee et al. 2017; Mardiastuti et al. 2021). Although scientific evidence supporting these claims is limited, the demand for snakes in local and international markets continues to rise, specifically for species such as Javan spitting cobra (*Naja sputatrix* (Boie, 1827)), which is native to Java, Bali, and Nusa Tenggara, Indonesia (Dafa et al. 2023).

Wild-caught snakes, specifically those intended for human consumption, are at an elevated risk of parasitic infections (Vasaruchapong et al. 2017). Exposure to diverse ecological environments and the stress associated with capture and transport increase susceptibility to parasitic invasions. Furthermore, snakes are known to harbor a broad range of internal parasites, including protozoans, nematodes, cestodes, pentastomids, acanthocephalans, and trematodes (Wolf et al. 2014; Mendoza-Roldán et al. 2020; Leung 2024). Some of these parasites, such as pentastomids (*Armillifer* spp. and *Porocephalus* spp.) (Tappe and Büttner 2009; Ioannou and Vamvoukaki 2019; Asemota et al. 2021) and cestodes (*Spirometra* spp.) (Liu et al. 2024), are zoonotic and pose significant risks to human health.

Various parasites infecting *Naja* species have been documented across different countries. For instance, internal parasites such as rhabditids and pentastomids have been identified in *N. kaouthia* in Thailand (Vasaruchapong et al. 2017). Nematodes of the genera *Capillaria*, *Kalicephalus*, and *Strongyloides*, alongside intestinal protozoa (*Isospora* sporocysts) and acanthocephalan worms, have been reported in *N. siamensis* in Thailand (Chaiyabutr and Chanhome 2002). In Iran, a comprehensive parasitological survey by Sazmand et al. (2024) documented the presence of haemoparasites such as *Hepatozoon* spp., alongside gastrointestinal nematodes, in the Caspian cobra (*Naja oxiana* (Eichwald, 1831)). The hemoparasite *Hepatozoon* was identified in *N. atra* in China (Huang et al. 2021), while cysts of *Sarcocystis* (Apicomplexa) were reported in *N. kaouthia* (Lesson, 1831) in Malaysia and *N. naja* (Linnaeus, 1758) in India (Bezerra et al. 2023).

In Indonesia, an earlier parasitological study of *N. sputatrix* reported infections with nematodes of the genus *Physaloptera* (Edila et al. 2023), *Kalicephalus* (Purwaningsih and Mumpuni 2011), and zoonotic cestode *Spirometra* (Yudhana et al. 2020). However, no comprehensive assessment of parasite diversity in *N. sputatrix* has been conducted. This is concerning given the increasing human-snake interface driven by culinary and commercial exploitation (Utama et al. 2024). The ecological role of *N. sputatrix* as a mesopredator further increases the likelihood of acquiring parasites from multiple trophic levels, particularly through prey items including rodents, amphibians, and lizards, which may serve as intermediate or paratenic hosts. These dynamics facilitate the maintenance and transmission of parasitic life cycles, many of which can cross species barriers under conducive conditions. From a One Health perspective, understanding the parasitological profile of *N. sputatrix* is essential not only for snake health and conservation but also for evaluating zoonotic risks posed to humans, specifically in settings where direct or indirect contact with the snake is common.

Despite the cultural and economic significance of *N. sputatrix*, parasitological data from wild populations in Indonesia remain highly fragmented. Considering the increasing demand for snake meat and the risk of zoonotic pathogen spillover, this study fills a critical knowledge gap by conducting the first systematic and multi-method parasitological investigation of *N. sputatrix* in Indonesia under a One Health framework. Based on the description above, this study aimed to investigate the diversity of internal parasites infecting wild-caught *N. sputatrix* in Sidoarjo, East Java, Indonesia.

MATERIALS AND METHODS

Ethical approval

This study was conducted with permission from the local Wildlife Conservation Department in East Java Province (SK.1/K2/BIDTEK.1/KSA/2024). *Naja sputatrix* is not categorized as an endangered species, and the populations are widely distributed in Indonesia. In addition, this study was reviewed and approved by the Animal Care and Use Committee of the Faculty of Veterinary Medicine, Universitas Airlangga, Indonesia (Vide No. 1.KEH.164.10.2023).

Study period and location

Naja sputatrix specimens were obtained from primary local sellers in Sidoarjo District, East Java, Indonesia, between September and December 2023. Sidoarjo is geographically located at latitude -7.4478 and longitude 112.7183. Parasitological examinations were conducted at Laboratory of Veterinary Parasitology, Faculty of Veterinary Medicine, Universitas Airlangga, Surabaya, Indonesia.

Snake sample identification

Naja sputatrix specimens were identified as wild-caught, as there are no captive breeding facilities for this species in the Sidoarjo District. Only snakes in good physical condition—defined as individuals without visible trauma or decomposition—were selected to ensure the integrity of necropsy and the accuracy of parasitological identification. A total of 51 specimens were examined and categorized into three age groups based on body length, including hatchlings (<40 cm), juveniles (40-80 cm), and adults (>80 cm). To provide visual references and enhance morphological understanding, detailed photographs were taken of key anatomical features, including the head, body, and tail (Figure 1).

Necropsy

Snakes were euthanized using chloroform anesthesia immediately before decapitation and examination for parasites, following established ethical protocols for reptile handling and necropsy. Parasitological examination was conducted according to the procedure described by Stacy (2020). After snakes were skinned, the muscular, visceral, and subcutaneous tissues were meticulously examined section by section. The internal organs were separated, opened, and washed in warm water. The resulting wash material was filtered through a 200 µm sieve, and parasites were recovered using sedimentation techniques. Recovered parasites were preserved in 70% ethanol for 24 hours, then transferred to alcohol-glycerol for clearing and mounting in glycerol gelatin. Morphological identification was carried out under a light microscope equipped with a digital camera (Nikon Eclipse e200; Olympus CX31).

Blood smear examination

Approximately 1 mL of blood was collected from the ventral coccygeal vein of each snake using a sterile 24 G needle. A portion of the whole blood was immediately used to prepare a smear, which was stained using the Dip Quick (Eosin and Methylene Blue) staining method (MDT IR®, Indonesia). The procedure comprised air-drying the blood smear at room temperature, fixing in methanol for 3 minutes, and sequentially staining in Eosin for 3 minutes and Methylene Blue for another 3 minutes. The smear was then rinsed under running water and air-dried at room temperature. Stained smears were examined at 1000× magnification under a light microscope equipped with a digital camera (Nikon Eclipse e200; Olympus CX31).

Coprological examination

Fecal samples were collected post-mortem by gently expressing the cloaca immediately following euthanasia and necropsy. The feces were brown to black, mixed with a white to yellow semi-solid mass of uric acid. The samples were examined using two techniques, namely a wet fecal smear for initial screening and fecal flotation for concentration. For wet fecal smears, a small amount of feces was mixed with a drop of 0.9% NaCl solution on a microscope slide. A coverslip (22 × 22 mm) was placed at one end of the slide and gently pushed to remove large debris, creating a uniform suspension under the coverslip.

Subsequently, microscopic examination was performed at 100× and 400× magnifications to identify potential parasites.

Coprological flotation technique was conducted following the method described by Wolf et al. (2014) using a saturated sugar solution as the flotation medium. Each sample was thoroughly homogenized in 50 mL preparation tubes (with sealing caps) containing approximately 15 mL of flotation solution using a vortexer. The homogenized suspension was strained into a 12 mL centrifuge tube, filled nearly to the top, and centrifuged at 300 g for 8-10 minutes. After centrifugation, the tube was carefully topped with flotation solution to form a convex meniscus. A coverslip was gently placed on the meniscus, left for 10 minutes, and then transferred onto a glass slide. The slides were examined microscopically at 100× magnification in a systematic meandering pattern. Suspicious structures were further analyzed at higher magnification, as needed, to confirm identification. The presence of helminth eggs, protozoan oocysts, and other parasitic elements was recorded to assess parasite diversity and prevalence.

RESULTS AND DISCUSSION

Parasite diversity and prevalence in *Naja sputatrix*

Parasitic infections were detected in 42 out of 51 *N. sputatrix* specimens (82.3%). Mixed infections were present in 36 specimens, while single infections were found in 6 (Table 1). Among adult snakes (>80 cm), 31 out of 35 specimens were infected (80.6%), including 25 mixed and 6 single infections. Among juvenile specimens (40-80 cm), 8 out of 12 were infected (66.7%), all presenting mixed infections. Among hatchlings (<40 cm), 3 out of 4 specimens were infected (75%), all with mixed infections (Table 1 and Table S1). A total of ten parasite taxa were identified, comprising four nematodes, one cestode, one acanthocephalan worm, one pentastomid, two enteric protozoa, and one hemoparasite (*Hepatozoon* spp.) (Table 2).

Taxonomic and generic identifications were based on established morphological keys and published diagnostic criteria, including Kuchta et al. (2024) for *Spirometra* spp.; Amin et al. (1998) and Amin (2013) for acanthocephalan larvae (*Sphaerechinorhynchus* spp.); Riley and Self (1979) and de Luna et al. (2022) for pentastomids (*Porocephalus* spp.); Schad (1962) for hookworm-like nematodes (*Kalicephalus* spp.); Šlapeta et al. (2017), Hallinger et al. (2020), and Ángel et al. (2022) for other gastrointestinal nematodes including *Capillaria* spp., *Strongyloides* spp., and *Ophidascaris* spp.; Abdel-Haleem et al. (2018) and Jameie et al. (2022) for hemoparasites (*Hepatozoon* spp.); Wolf et al. (2014) and Hallinger et al. (2020) for protozoan cysts and oocysts (*Balantidium* spp., *Eimeria* spp.). Ecological terminology used in the description of host-parasite relationships follows Bush et al. (1997).

Table 1. Prevalence and infection patterns of endoparasites in wild-caught *Naja sputatrix* based on age group from Sidoarjo, East Java, Indonesia

Age of *Naja sputatrix*	Number of samples (N)	Positive samples	Type of infections		Prevalence %
			Mixed	Single	
Hatchling (<40 cm)	4	3	3	0	75%
Juvenile (40-80 cm)	12	8	8	0	66.7%
Adult (>80 cm)	35	31	25	6	80.6%
Total	51	42	36	6	82.3%

Table 2. Prevalence and infection sites of endoparasites identified in wild-caught *Naja sputatrix* from Sidoarjo, East Java, Indonesia

Parasites	Stage	Source/site	No. infected/No. exanined	Prevalence (%)
Nematoda				
Capillaria (Syn. *Ophidiocapillaria*) spp.	Eggs	F	5/51	9.8
Strongyloides spp.	Larva; Eggs	F	13/51	25.49
Kalicephalus spp.	Adult; Eggs	S, C & F	17/51	33.33
Ophidascaris spp.	Adult; Eggs	SI & F	4/51	7.84
Cestoda				
Spirometra spp.	Larva	M, ST, BC	28/51	54.9
Acanthocephala				
Sphaerechinorhynchus spp.	Larva	M, ST, BC	24/51	47.05
Pentastomida				
Porocephalus spp.	Adult	BC	6/51	11.76
Enteric protozoa				
Balantidium spp.	Cyst; Trophozoite	F	1/51	1.96
Eimeria spp.	Oocyst	F	6/51	11.76
Hemoparasite				
Hepatozoon spp.	Gametocyte	B	15/51	29.41

Note: F: Fecal, SI: Small Intestine, S: Stomach, C: Colon, M: Musculature, ST: Subcutaneous Tissue, BC: Body Cavity, B: Blood. Detailed parasitic profiles of wild-caught *Naja sputatrix* are described in Table S1

The zoonotic cestode *Spirometra* spp. was the only tapeworm detected. Larvae (plerocercoids) were found in 28 of 51 *N. sputatrix* specimens (54.9%). Plerocercoids were located in the musculature, subcutaneous tissues, and body cavities (Figure 2.A). The larvae showed characteristic bothria on the rudimentary scolex (Figure 4.C). Morphologically, the spargana were elongated, ribbon-like, and whitish to translucent in appearance, with a pseudo-segmented body structure measuring approximately 40-75 mm in length (Figure 3.C). Zoonotic pentastomids of the genus *Porocephalus* were detected in 6 out of 51 examined *N. sputatrix* specimens (11.76%). Larvae were primarily located in the respiratory tract. The body was cylindrical, annulated, and measured 8-13 mm in length (Figure 3.D). The cephalothorax was rounded and not distinctly separated from the trunk; the anterior region was continuous with the trunk without a neck constriction. The oral aperture was positioned between or posterior to the internal oral hooks, and no sclerotized mouthparts were observed. The trunk was cylindrical and lacked ventral expansion (Figure 4.D).

Four nematode genera were identified in this study. *Capillaria* eggs were found in fecal samples from 5 out of 51 snakes (9.8%). The eggs were characterized by the barrel-shaped form, thick walls, and prominent bipolar plugs (Figure 5.A). *Strongyloides* parasites were identified in 13 samples (25.49%), with the eggs showing an oval shape, thin walls, and segmented embryonic cells inside (Figures 5.B and 5.E). In several fecal samples, *Strongyloides* larvae were also observed (Figure 5.C). *Ophidascaris* eggs were detected in 4 samples (7.84%), with an oval to elliptical shape, thick shells, and smooth surfaces having a slightly granular interior (Figure 5.D). During necropsy, adult *Ophidascaris* worms were recovered from the small intestine (Figure 2.C), measuring approximately 40-110 mm in length. These worms were characterized by elongated, cylindrical bodies with tapered anterior ends and prominent mouth openings, each surrounded by three well-developed lips (Figures 3.A and 4.A). Lastly, *Kalicephalus* spp., a hookworm-like nematode, was the most prevalent nematode identified, detected in 17 out of 51 snakes (33.33%). These species are morphologically similar to hookworms and distinguished by a narrow oral opening, a bivalval buccal cavity, and prominent papillae (Schad 1962). Eggs were found in feces, characterized by an oval shape, thin shells, and embryonated interiors with larvae at an advanced developmental stage (Figure 5.E). Adult *Kalicephalus* worms were present in the stomach and colon, measuring approximately 8-12 mm in length (Figure 3.B). Identification was based on the strongly developed buccal capsule with dorsal teeth (Figure 4.B).

Larval stages (cystacanths) of acanthocephalans belonging to the genus S*phaerechinorhynchus* were identified in 24 out of 51 *N. sputatrix* (47.05%). The cystacanth larvae were elongated, slightly curved, and enclosed in cysts, with a white coloration and a length ranging from 25-40 mm (Figure 3.D). The larvae were found in the musculature, subcutaneous tissues, and body cavities (Figure 2.B). Microscopic examination showed three anterior hooks with simple roots and five to six posterior rootless spines (Figure 4.D). The enteric protozoa identified in this study included *Balantidium* spp. and *Eimeria* spp. *Balantidium* spp. were found in a single fecal sample (1.96%), appearing in both trophozoite and cyst forms. The cysts were characterized by thick, refractile walls, a diagnostic feature (Figure 5.G). Meanwhile, the trophozoites had rows of cilia covering the surfaces and a cytostome at one pole (Figure 5.F). The rotary movement of the trophozoites further confirmed the identification as *Balantidium* spp., consistent with previous morphological descriptions (Wolf et al. 2014). In addition, coccidian oocysts consistent with *Eimeria* spp. were detected in 6 out of 51 fecal samples (11.76%). These oocysts were oval-shaped, with a double-layered wall featuring a smooth outer surface and visible internal sporoblasts or fully developed sporocysts (Figure 5.H). The hemoparasite *Hepatozoon* spp. was detected in 6 out of 51 blood samples (11.76%). Gamonts were oval and located intracellularly within erythrocytes; the central nucleus was distinct (Figure 6.A). Double gamonts were occasionally observed within single red blood cells (Figure 6.B).



Figure 1. Morphological characteristics of wild-caught Javan spitting cobra *(Naja sputatrix)* from Sidoarjo, East Java, Indonesia, which were used as specimens in the current study: A. Lateral view of the snake's head, B. Lateral view of the snake's body, and C. Tail of the snake

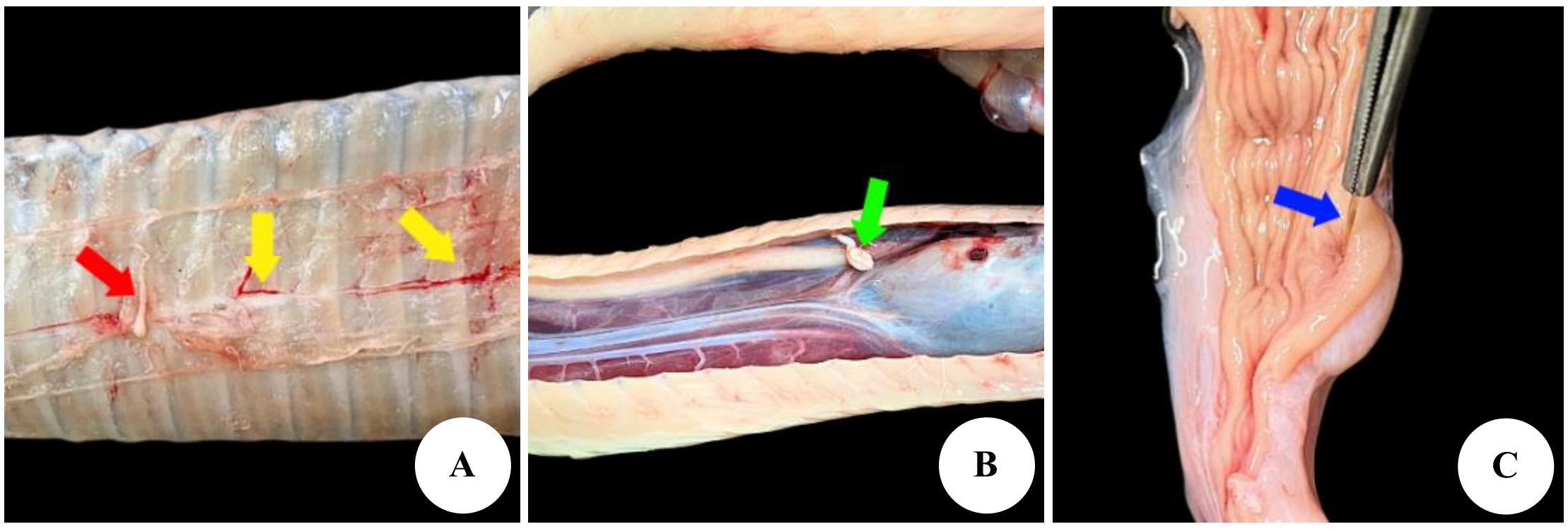

Figure 2. Predilection sites of parasitic worms observed during necropsy of Javan Spitting Cobra snakes (*Naja sputatrix*). A. Plerocercoid larvae of *Spirometra* spp. located in the subcutaneous tissue (indicated by red arrow), accompanied by hemorrhagic regions at the site of infection (yellow arrow), B. Cystacanth larvae of the acanthocephalan worm *Sphaerechinorhynchus* spp. identified within the body cavity of the snake (green arrow), C. Adult *Ophidascaris* spp. observed attached to the wall of the small intestine (blue arrow)



Figure 3. Macroscopic appearance of helminth parasites found in Javan spitting cobra snakes (*Naja sputatrix*) during necropsy: A. *Ophidascaris* spp., adult stage, B. *Kalicephalus* spp., C. *Spirometra* spp., plerocercoid (spargana) stage, D. *Sphaerirohynchus* spp. (Acanthocephalan worm), cystacanth (larval stage), E. *Porocephalus* spp. (pentastomid group)

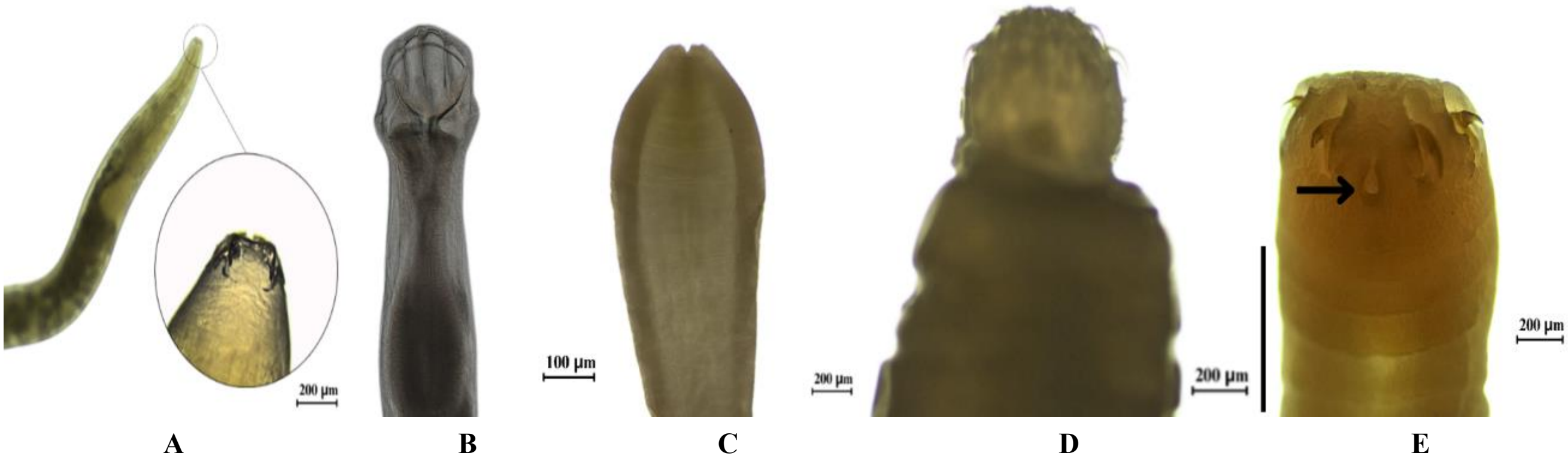

Figure 4. Microphotographs of helminth parasites found in Javan spitting cobra snakes (*Naja sputatrix*). A. *Ophidascaris* spp., dorsal view of the anterior end showing three well-developed lips, B. *Kalicephalus* spp., anterior end with a buccal capsule showing four pairs of sclerotized plates, C. *Spirometra* spp., lateral view of the anterior end of a tapeworm larvae, D. *Sphaerechinorhynchus* spp., anterior end of an acanthocephalan larva in lateral view, E. *Porocephalus* spp., anterior end showing the mouth located between the internal oral hooks (black arrow), and a cephalothorax without obvious differentiation from the trunk (black line)

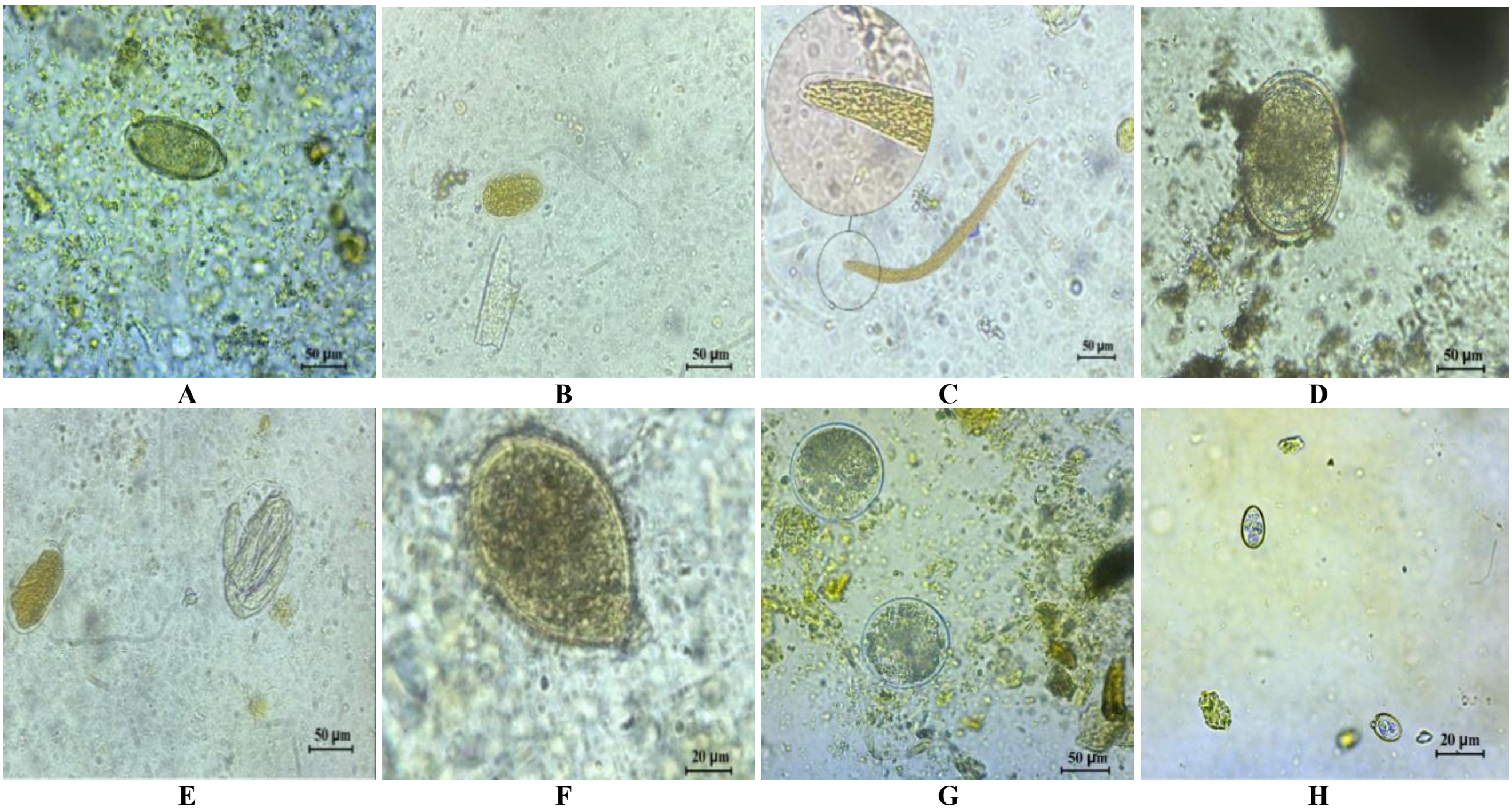

Figure 5. Microphotographs of carious parasitic stages identified in *Naja sputatrix* through fecal sample analysis: A. Egg of *Capillaria* (Syn. *Ophidiocapillaria*) spp. within a direct smear, B. Embryonated eggs of *Strongyloides* species within a flotation, C. Infective third-stage larva of *Strongyloides* spp., displaying an engrailed tail-tip, within a direct smear, D. Ascarid egg (*Ophidascaris* spp.) within a flotation, E. Embryonated eggs of *Strongyloides* spp. (right) and strongyle-type (*Kalicephalus*-like; left) within a flotation, F. Trophozoite of *Balantidium* spp. within a direct smear, G. Ciliate cyst (*Balantidium* spp.) within a direct smear, H. Oocyst of *Eimeria* spp. within a flotation

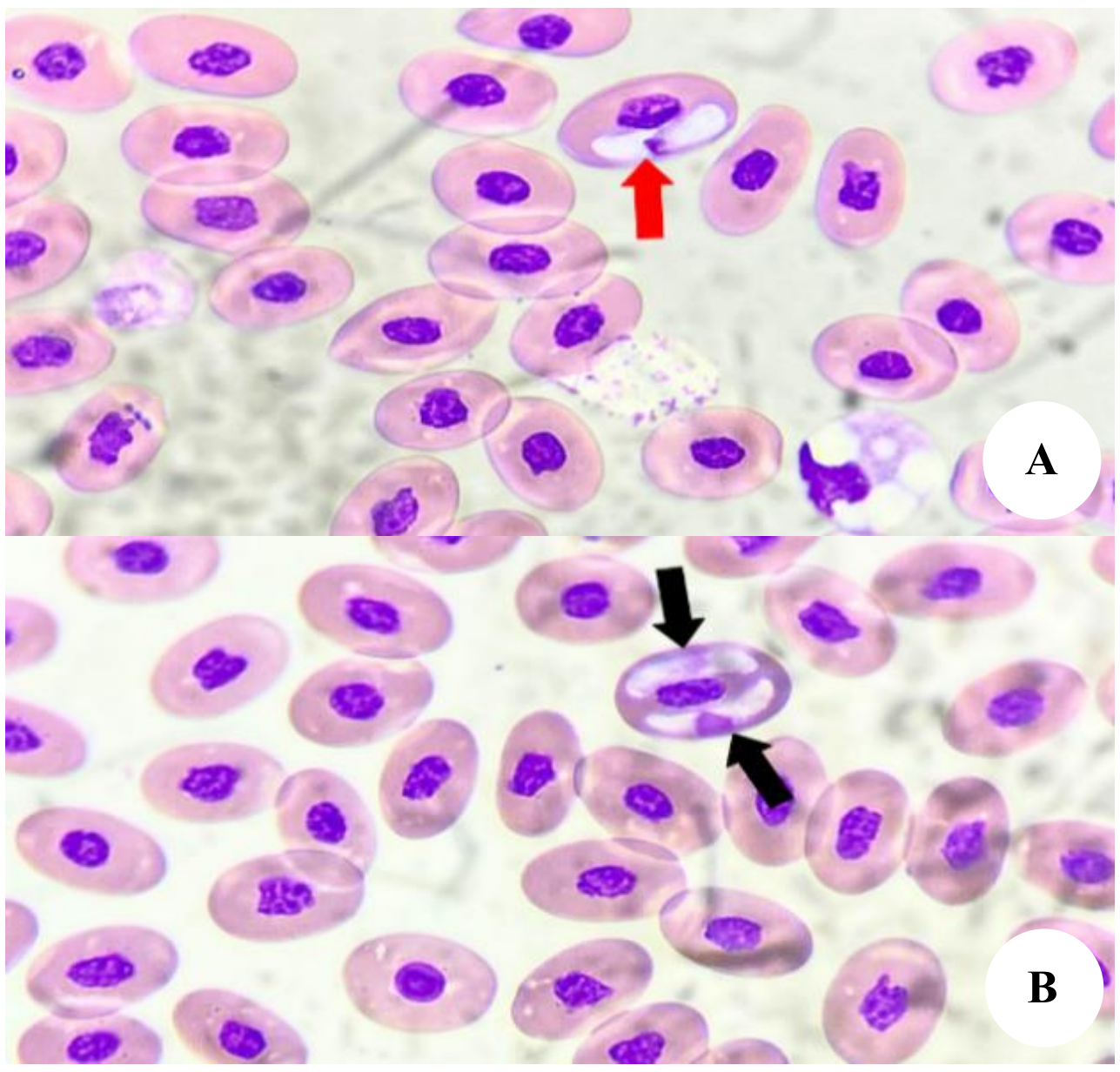

Figure 6. Blood smear photomicrographs showing intraerythrocytic gamonts of *Hepatozoon* spp. in Javan spitting cobra (*Naja sputatrix*). A. A single gamont of *Hepatozoon* spp. (red arrow) observed within the cytoplasm of an erythrocyte, characterized by an elongated shape with a centrally located nucleus, B. Double infection of *Hepatozoon* spp. gamonts (black arrows) within a single erythrocyte, showing two distinct gamonts in one host cell. Blood smear stained with Dip Quick stain and examined under a light microscope at 1000× magnification

Discussion

Snakes, including *N. sputatrix*, function as both predator and prey in natural ecosystems, contributing to ecological balance. This trophic duality facilitates exposure to a broad range of parasitic infections, rendering snakes potential reservoirs for zoonotic pathogens (Mendoza-Roldán et al. 2020). Human-snake interactions increase the risk of cross-species transmission. High prevalence of *Spirometra* infection in *N. sputatrix* supports the role of snakes as second intermediate or paratenic hosts in the parasite's life cycle. The life cycle of *Spirometra* spp. involves three host types: definitive (carnivores), first intermediate (freshwater copepods), and second intermediate/paratenic hosts, including amphibians, reptiles, birds, and mammals (Liu et al. 2024). Plerocercoids localized in the visceral, muscular, and subcutaneous tissues of *N. sputatrix* indicate their potential for tissue migration, leading to nodule formation and localized inflammation. These pathological features are commonly reported in reptilian hosts and reflect zoonotic risks associated with the ingestion of raw or undercooked amphibian or reptile meat, contaminated water, or traditional poultices (Kuchta et al. 2024).

The present findings are consistent with previous records of *Spirometra* plerocercoid infection in snakes, including *Naja samarensis* (Peters, 1861) (USA), *Ptyas korros* (Schlegel, 1837) (Thailand), and *Naja atra* (Cantor, 1842) (China) (Jongthawin et al. 2014; Gong et al. 2022; Verocai et al. 2023). In Indonesia, several cases of *Spirometra* plerocercoid infection have been reported in snakes

(Pranashinta et al. 2017; Yudhana et al. 2020; Bagaskara et al. 2023; Iskandar et al. 2024), as well as adult worms in carnivorous hosts such as canids and felids (Margono et al. 2007; Okamoto et al. 2007). The public health importance of *Spirometra* infection is further reinforced by numerous clinical reports of human sparganosis. To date, over 2,500 cases have been reported globally, including more than 1,300 in China, over 500 in Japan, more than 400 in Korea, approximately 100 in Thailand, about 50 in the United States, and 18 in Europe (11 indigenous, 7 immigrant) (Wiwanitkit 2005; Sabu et al. 2015). A retrospective analysis of 438 Korean cases (1924-2015) attributed 63% to ingestion of infected frog and snake meat and 17% to consumption of unfiltered water (Kim et al. 2018).

Similarly, *Porocephalus* spp. is a zoonotic pentastomid parasite reported in reptiles, particularly snakes. Adult stages are localized in the respiratory tract of reptilian hosts. Larval forms (nymphs) develop within visceral organs of intermediate hosts, including mammals. The term pentastome originates from a historical misinterpretation, in which the organism's four anterior hooks and single mouth were mistaken as five separate mouths. Morphological criteria, particularly cephalothoracic continuity and the absence of a globose anterior end, are distinguishable from those of related genera such as *Kiricephalus* (Riley and Self, 1979; Christoffersen and De Assis 2013). The present report constitutes the first record of *Porocephalus* from snakes in Indonesia. Pentastomes are annulated, blood-feeding, unsegmented endoparasites. Their morphological characteristics exhibit affinities with both Arthropoda and Annelida; however, they are currently retained within their own phylum (Yao et al. 2008). The genus is classified among five pentastomid taxa of zoonotic concern, along with *Armillifer* spp., *Linguatula* spp., *Leiperia* spp., and *Raillietiella* spp. (Barton and Shamsi 2024).

Human pentastomiasis was first described by Pruner (1847) in Egypt and has since been predominantly reported from endemic regions in Africa and Asia (Ranque et al. 1974; Faisy et al. 1995). Human infections are caused by the ingestion of infective eggs or nymphs. Two clinical forms have been described (Ma et al. 2002): (1) Visceral pentastomiasis, acquired through the ingestion of embryonated eggs, in which humans act as accidental intermediate hosts. Infective stages are transmitted through contact with soil, vegetation, or water contaminated by respiratory secretions or feces of definitive hosts, including snakes. Direct transmission has also been reported through the handling or consumption of infected reptilian tissues. (2) Nasopharyngeal pentastomiasis, acquired through the ingestion of nymphs, in which humans serve as aberrant definitive hosts. Clinical manifestations are often nonspecific, and asymptomatic cases are frequent. Misdiagnosis is common in non-endemic settings (Yao et al. 2008; Barton and Shamsi 2024).

Kalicephalus nematodes were identified in the stomach and colon of infected snakes. These parasites attach to the host’s mucosa using a specialized kalicephalic buccal capsule equipped with teeth that allow penetration into tissue and blood vessels (Larki et al. 2023). As hematophagous (blood-feeding) parasites, *Kalicephalus* spp. are capable of causing significant pathology, ranging from mild enteritis to severe and often fatal hemorrhagic-necrotic gastroenteritis. Secondary bacterial infections often complicate such conditions (Schad 1962; Larki et al. 2023). Other nematode genera found in this study, including *Capillaria* spp., *Strongyloides* spp., and *Ophidascaris* spp., have also been frequently reported in reptiles (Šlapeta et al. 2017). *Capillaria* spp. are commonly associated with wild snakes such as *Bothrops asper* (Garman, 1883) (Ángel et al. 2022), colubrids including *Ptyas mucosa* (Linnaeus, 1758) and *Dolichophis jugularis* (Linnaeus, 1758), and vipers, namely *Trimeresurus albolabris* (Gray, 1842) (Hallinger et al. 2020). *Ophidascaris* spp. have been widely reported in terrestrial snakes (Ángel et al. 2022), as well as in several viper species from Indonesia (Mairawita et al. 2024). Crucially, recent literature has confirmed *Ophidascaris* as a zoonotic genus. *Ophidascaris robertsi*, in particular, has been recognized as an emerging neurotropic parasite in humans, with documented cases of larvae recovered from the human brain (Daungsupawong and Wiwanitkit 2024). Additional reports highlight the presence of *Ophidascaris* larvae across ecological biotopes in Nigeria, emphasizing their zoonotic capacity and ecological adaptability (Aisien et al. 2025). Although molecular confirmation was not conducted in this study, the presence of *Ophidascaris* spp. in wild-caught *N. sputatrix* suggests a potential risk for transmission in endemic areas.

Strongyloides spp. have been extensively documented in *Naja kaouthia* (Lesson, 1831) (Vasaruchapong et al. 2017) and in other snakes such as *Leptodeira annulata* (Linnaeus, 1758), *Imantodes cenchoa* (Linnaeus, 1758), and *Boa constrictor* (Linnaeus, 1758) (Ángel et al. 2022), across various families including Pythonidae, Colubridae, Boidae, Viperidae, Lamprophiidae, and Elapidae (Hallinger et al. 2020). The occurrence of these nematodes reflects broad adaptability and the ecological role of *N. sputatrix* as a host for diverse nematode species with both direct and indirect life cycles. The relatively high prevalence of *Sphaerechinorhynchus* spp. infection in this study supports the role of *N. sputatrix* as a paratenic host. Definitive hosts of acanthocephalans are primarily carnivorous mammals and predatory birds, while snakes function mainly as transport or paratenic hosts, acquiring the cystacanth stage from infected prey (Komorová et al. 2015; Richardson et al. 2017; Edila et al. 2024). Acanthocephalan larvae have previously been reported in *Xenochrophis piscator* (Schneider, 1799) in Indonesia (Audini et al. 2017), supporting the transmission potential among snakes of similar size and trophic habits. The larvae observed in the present specimens were morphologically consistent with *Sphaerechinorhynchus* spp. The proboscis was armed with recurved hooks arranged in longitudinal rows, with fully everted structures observable under microscopy (Amin et al. 1998; Amin 2013). Comparable larval morphotypes have been recorded in *N. naja* and *Ophiophagus hannah* (Cantor, 1836) from Borneo and Thailand (Schmidt and Kuntz 1966).

The detection of protozoa in wild-caught *N. sputatrix* likely reflects environmental contamination. *Eimeria* spp., possessing a direct (monoxenous) life cycle, require only a single host, enabling efficient transmission via the fecal-oral route. Sporulated oocysts, containing four sporocysts, are environmentally resistant and facilitate persistence in contaminated substrates. Similar oocysts have been described in *Philothamnus semivariegatus* (Smith, 1840), *Boa constrictor* (Linnaeus, 1758) (Hallinger et al. 2020), and *Hierophis viridiflavus* (Lacépède, 1789) (Mendoza-Roldán et al. 2024). The presence of *Balantidium* spp. may be attributed to the ingestion of cyst-contaminated food or water (Lobão et al. 2023). However, pseudoparasitism remains a possible explanation. Wild snakes frequently consume prey species (e.g., rodents, amphibians) that serve as reservoirs for intestinal protozoa. The non-infective passage of protozoan stages through the gastrointestinal tract has been documented in several ophidian hosts (Wolf et al. 2014; Hallinger et al. 2020). Therefore, the detection of *Eimeria* and *Balantidium* spp. may not confirm active infection, but rather reflect the transient gut passage of prey-derived parasites.

The identification of *Hepatozoon* spp. in *N. sputatrix* underscores the exposure of wild snakes to vector-borne parasites. Identification of this genus primarily relies on the morphological features of two life cycle stages, namely gamonts in the blood of vertebrate hosts and polysporocystic oocysts located in the gut of invertebrate vectors (Abdel-Haleem et al. 2018). *Hepatozoon* spp. are considered among the most common hemogregarine parasites infecting snakes, with infections reported in over 200 snake species worldwide (Jameie et al. 2022). Among snakes, *Hepatozoon* spp. have been identified as common blood parasites, with transmission facilitated by hematophagous arthropods, including mosquitoes (Culicidae), ticks, and mites (Ángel et al. 2022).

A limitation of this study is the exclusive reliance on morphological methods without molecular confirmation. However, the morphological features used for genus-level identification were consistent with those described in recent taxonomic keys and parasitological reports. Future studies are encouraged to incorporate genetic tools to improve species-level resolution.

In conclusion, this study provides the first comprehensive parasitological survey of wild-caught *N. sputatrix* in Indonesia, revealing a high prevalence (82.3%) of diverse endoparasites. Ten parasite taxa were identified, including nematodes, cestodes, acanthocephalans, pentastomids, protozoa, and hemoparasites, with adult snakes showing the highest infection rates. Zoonotic parasites such as *Spirometra* spp. (54.9%), *Porocephalus* spp. (11.76%), and *Ophidascaris* spp. (7.84%) were detected. Notably, this study represents the first host record of *Porocephalus* spp. in *N. sputatrix*, providing novel ecological insight into host-parasite relationships in venomous snakes. These findings demonstrate not only the susceptibility of *N. sputatrix* to multiple infections but also its ecological role as a reservoir and paratenic host. Importantly, parasite surveillance in snakes can serve as an early warning tool for wildlife trade monitoring and biosecurity risk assessment, particularly in regions with high levels of human-snake interaction. Moreover, parasitological data from wild reptiles offer valuable insights for biodiversity and environmental health monitoring within a One Health framework.

ACKNOWLEDGEMENTS

The authors are grateful to the Ministry of Higher Education, Science, and Technology of the Republic of Indonesia for supporting this research through the 2025 Master-to-Doctorate Program for Outstanding Graduates (PMDSU), with grant number from Universitas Airlangga: 2461/B/UN3.LPPM/PT.01.03/2025.

REFERENCES

Abdel-Haleem HM, Mansour L, Holal M, Qasem MAA, Al-Quraishy S, Abdel-Baki A-AS. 2018. Molecular characterisation of *Hepatozoon aegypti* Bashtar, Boulos & Mehlhorn, 1984 parasitising the blood of *Spalerosophis diadema* (Serpentes: Colubridae). Parasitol Res 117 (10): 3119-3125. DOI: 10.1007/s00436-018-6006-4.

Aisien MSO, Imasuen AA, Edo-Taiwo O, Awharitoma A, Ogoanah SO, Ozemoka HJ, Aijehi OJ, Onaiwu B. 2025. Human *Ophidascaris* infection: A possibility in all ecological biotopes of Nigeria. Niger J Parasitol 46 (1): 91-98. DOI: 10.4314/njpar.v46i1.10.

Amin OM, Wongsawad C, Marayong T, Saehoong P, Suwattanacoupt S, Sey O. 1998. *Sphaerechinorhynchus macropisthospinus* sp. n. (Acanthocephala: Plagiorhynchidae) from lizards, frogs, and fish in Thailand. J Helminthol Soc Wash 65 (2): 174-178.

Amin OM. 2013. Classification of the Acanthocephala. Folia Parasitol 60 (4): 273-305. DOI: 10.14411/fp.2013.031.

Ángel LMA, Crespo Ortiz MDP, Bolívar García W. 2022. Parásitos asociados a ofidios del Pacífico colombiano. Rev Arg Parasitol 11 (2): 17-27.

Asemota J, Talbet J, Igbinosa O, Igbinovia O. 2021. Disseminated *Armillifer armillatus* infestation: A rare cause of acute abdomen. Cureus 13 (5): e15038. DOI: 10.7759/cureus.15038.

Audini IS, Suwanti LT, Koesdarto S, Poetranto ED. 2017. Acanthocephalan in *Xenochrophis piscator* snake in Sidoarjo, Indonesia. KnE Life Sci 3 (6): 21-27. DOI: 10.18502/kls.v3i6.1102.

Bagaskara R, Lukiswanto BS, Rahardjo AP, Poetranto ED, Koesdarto S, Mufasirin M. 2023. Detection of spargana on *Ptyas korros* in Sidoarjo. Jurnal Medik Veteriner 6 (3): 122-125. DOI: 10.20473/jmv.vol6.iss3.2023.122-125.

Barton DP, Shamsi S. 2024. Diagnosis of pentastome infections and the need for increased awareness among medical practitioners and diagnosticians in the developed world. Curr Clin Microbiol Rep 11: 79-87. DOI: 10.1007/s40588-024-00245-z.

Bezerra TL, Soares RM, Gondim LFP. 2023. *Sarcocystis* species (Apicomplexa, Eucoccidiorida) parasitizing snake. Parasitologia 3 (4): 327-347. DOI: 10.3390/parasitologia3040032.

Bush AO, Lafferty KD, Lotz JM, Shostak AW. 1997. Parasitology meets ecology on its own terms: Margolis et al. revisited. J Parasitol 83 (4): 575-583. DOI: 10.2307/3284227.

Chaiyabutr N, Chanhome L. 2002. Parasites in Snake of Thailand. Bull Md Herpetol Soc 38 (2): 39-49.

Christoffersen ML, De Assis JE. 2013. A systematic monograph of the recent *Pentastomida*, with a compilation of their hosts. Zool Med Leiden 87 (1): 1-206.

Dafa MH, Yudha DS, Sulistio AD. 2023. Preliminary study on morphology, meristics, and morphometric variations of Javan spitting cobra *Naja sputatrix* Boie, 1827 and Sumatran spitting cobra *Naja sumatrana* Müller, 1890. Genbinesia: J Biol 3 (1): 31-40. DOI: 10.55655/genbinesia.v3i1.61.

Daungsupawong H, Wiwanitkit V. 2024. Ophidascaris robertsi, the new emerging human parasite and neurosurgery. Formos J Surg 57 (2): 78. DOI: 10.1097/FS9.0000000000000092.

de Luna M, García-Barrios R, Barton DP, Guajardo-Martínez G. 2022. Tongue worm (Pentastomida) parasites of North American herpetofauna: Checklist of species, identification key, and new state and host records from Mexico. J Parasitol 108: 582-594. DOI: 10.1645/22-52.

Edila R, Effendi MH, Suwanti LT, Kwon HK, Agumah NB. 2024. Novel exploration of the presence and morphological features of *Spirometra* (Cestoda: Diphyllobothriidae) in Javan spitting cobra snakes (*Naja sputatrix*) in Sidoarjo, Indonesia. Biodiversitas 25 (8): 3318-3324. DOI: 10.13057/biodiv/d250803.

Edila R, Effendi MH, Suwanti LT, Kwon H-K, Yudhana A, Wardhana AH, Alhada A. 2024. A comprehensive study on the occurrence rate and morphological characteristics of the acanthocephalan parasite in Javan spitting cobra (*Naja sputatrix*) in Sidoarjo, Indonesia. Biodiversitas 25 (2): 516-521. DOI: 10.13057/biodiv/d250210.

Edila R, Yudhana A, Praja RN. 2023. First report of *Physaloptera* (Nematoda: Physalopteridae) parasitizing Javan spitting cobra snake (*Naja sputatrix*) in Indonesia. AIP Conf Proc 2431: 030002. DOI: 10.1063/5.0115940.

Faisy C, Boye B, Blatt A, Boutes P, Iloumbou J. 1995. Porocephalosis, a little known parasitosis: Literature review and a Congolese case report. Méd Trop 55 (3): 258-262.

Gong T, Su X, Li F, He J, Chen S, Li W, Xie X, Liu Y, Zhang X, Liu W. 2022. Epidemiology and genetic diversity of *Spirometra* tapeworm isolates from snakes in Hunan Province, China. Animals 12 (9): 1216. DOI: 10.3390/ani12091216.

Hallinger MJ, Taubert A, Hermosilla C. 2020. Occurrence of *Kalicephalus*, *Strongyloides*, and *Rhabdias* nematodes as most common gastrointestinal parasites in captive snakes of German households and zoological gardens. Parasitol Res 119: 947-956. DOI: 10.1007/s00436-019-06526-0.

Huang N, Wu Y, Li Y, Zhao J. 2021. A new record of *Hepatozoon* sp. Miller, 1908 (Apicomplexa: Adelerina) infecting the snake *Naja atra* (Squamata: Elapidae) in China. Pak J Zool 53 (6): 2167-2173. DOI: 10.17582/journal.pjz/20200218070217.

Ioannou P, Vamvoukaki R. 2019. *Armillifer* infections in humans: A systematic review. Trop Med Infect Dis 4 (2): 80. DOI: 10.3390/tropicalmed4020080.

Iskandar MDI, Dewi K, Apriyanti Y, Budjiastuti W. 2024. Catatan baru larva *Spirometra* sp. (Cestoda: Diphyllobothriidea) pada katak sawah, *Fejervarya cancrivora*, di Leuwiliang, Kabupaten Bogor, Jawa Barat. Sains dan Matematika 9 (2): 60-63. [Indonesian]

Jameie F, Nasiri V, Paykari H. 2022. Morphological detection and molecular characterization of *Hepatozoon* spp. from venomous terrestrial snakes in Iran. Exp Parasitol 239: 108309. DOI: 10.1016/j.exppara.2022.108309.

Jongthawin J, Intapan PM, Sanpool O, Sadaow L, Laymanivong S, Thanchomnang T, Maleewong W. 2014. Molecular evidence of *Spirometra erinaceieuropaei* infection in the snake *Ptyas korros* from Lao PDR and Thailand and the frog *Hoplobatrachus rugulosus* from Myanmar. Southeast Asian J Trop Med Public Health 45 (6): 1271-1278.

Kim J-G, Ahn C-S, Sohn W-M, Nawa Y, Kong Y. 2018. Human sparganosis in Korea. J Korean Med Sci 33: e273. DOI: 10.3346/jkms.2018.33.e273.

Komorová P, Špakulová M, Hurníková Z, Uhrín M. 2015. Acanthocephalans of the genus *Centrorhynchus* (Palaeacanthocephala: Centrorhynchidae) of birds of prey (Falconiformes) and owls (Strigiformes) in Slovakia. Parasitol Res 114 (6): 2273-2278. DOI: 10.1007/s00436-015-4420-4.

Kuchta R, Phillips AJ, Scholz T. 2024. Diversity and biology of *Spirometra* tapeworms (Cestoda: Diphyllobothriidea), zoonotic parasites of wildlife: A review. Intl J Parasitol Parasites Wildl 23: 100947. DOI: 10.1016/j.ijppaw.2024.100947.

Larki S, Alborzi A, Bahramnejad K, Asadi Z. 2023. The occurrence of the strongylid nematode *Kalicephalus viperae viperae* (Nematoda: Diaphanocephalidae) in viper snakes *Macrovipera lebetina* (Reptilia: Viperidae) in Southwestern Iran. Arch Razi Inst 78 (2): 611-618. DOI: 10.22092/ARI.2022.359446.2418.

Leung TLF. 2024. Zoonotic parasites in reptiles, with particular emphasis on potential zoonoses in Australian reptiles. Curr Clin Microbiol Rep 11: 88-98. DOI: 10.1007/s40588-024-00221-0.

Liu W, Gong T, Chen S, Liu Y. 2024. *Spirometra*. In: Tang YW, Sails AD (eds). Molecular Medical Microbiology. 3rd ed. Academic Press, London. DOI: 10.1016/B978-0-12-818619-0.00020-4.

Lobão LF, Corrêa LL, Bruno SF, da Silva S, Uchôa CMA, da Silva Barbosa A. 2023. Diagnosis of endoparasite species and subtypes of *Cryptosporidium* spp. with one health importance in feces from captive snakes in Rio de Janeiro, Brazil. Parasitol Intl 97: 102797. DOI: 10.1016/j.parint.2023.102797.

Ma KC, Qiu MH, Rong YL. 2002. Pathological differentiation of suspected cases of pentastomiasis in China. Trop Med Intl Health 7 (2): 166-177. DOI: 10.1046/j.1365-3156.2002.00839.x.

Mairawita M, Herwina H, Hidayat F, Janra MN, Diniyati F. 2024. Prevalence of gastrointestinal parasites in vipers (Serpentes: Viperidae) reared in Padang City, West Sumatra, Indonesia. Biodiversitas 25 (4): 1352-1358. DOI: 10.13057/biodiv/d250402.

Mardiastuti A, Masy'ud B, Ginoga LN, Sastranegara H, Sutopo. 2021. Overview of the traditional Indonesian knowledge on the use of reptiles. IOP Conf Ser: Earth Environ Sci 716: 012066. DOI: 10.1088/1755-1315/716/1/012066.

Margono SS, Sutjahyono RW, Kurniawan A, Nakao M, Mulyani T, Wandra T, Ito A. 2007. Diphyllobothriasis and sparganosis in Indonesia. Trop Med Health 35 (4): 301-305. DOI: 10.2149/tmh.35.301.

Mendoza-Roldán JA, Modrý D, Otranto D. 2020. Zoonotic parasites of reptiles: A crawling threat. Trends Parasitol 36 (8): 677-687. DOI: 10.1016/j.pt.2020.04.014.

Mendoza-Roldán JA, Perles L, Filippi E, Szafranski N, Montinaro G, Carbonara M, Scalera R, de Abreu Teles PP, Walochnick J, Otranto D. 2024. Parasites and microorganisms associated with the snake collected for the "Festa dei Serpari" in Cocullo, Italy. PLoS Negl Trop Dis 18 (2): e0011973. DOI: 10.1371/journal.pntd.0011973.

Mukherjee S, Gomes A, Dasgupta SC. 2017. Zoo therapeutic uses of snake body parts in folk and traditional medicine. J Zool Res 1 (1): 1-9. DOI: 10.22259/2637-5575.0101001.

Okamoto M, Iseto C, Shibahara T, Sato MO, Wandra T, Craig PS, Ito A. 2007. Intraspecific variation of *Spirometra erinaceieuropaei* and phylogenetic relationship between *Spirometra* and *Diphyllobothrium* inferred from mitochondrial CO1 gene sequences. Parasitol Intl 56 (3): 235-238. DOI: 10.1016/j.parint.2007.03.003.

Pranashinta GT, Suwanti LT, Koesdarto S, Poetranto ED. 2017. *Spirometra* in *Ptyas mucosus* snake in Sidoarjo, Indonesia. KnE Life Sci 3 (6): 34-40. DOI: 10.18502/kls.v3i6.1104.

Pruner F. 1847. Die Krankheiten des Orient's vom Standpunkte der vergleichenden Nosologie betrachtet. Palm & Enke, Erlangen. [German]

Purwaningsih E, Mumpuni. 2011. New host and locality records of snake intestinal nematode *Kalicephalus* spp. in Indonesia. Asian Pac J Trop Biomed 1 (2): 121-123. DOI: 10.1016/S2221-1691(11)60008-7.

Ranque P, Amy D, Discamps G, Mattei X, Quilici M. 1974. Pentastomiasis by *Armillifer armillatus*. Z Parasitenkunde 44: 329-338. DOI: 10.1007/BF00366115.

Richardson DJ, Smales LR, Ghorbani MN, Halajian A. 2017. *Centrorhynchus* spp. (Acanthocephala: Centrorhynchidae) from stray dogs *Canis familiaris* in Qom, Iran. Comp Parasitol 84 (2): 159-162. DOI: 10.1654/1525-2647-84.2.159.

Riley J, Self JT. 1979. On the systematics of the pentastomid genus *Porocephalus* (Humboldt, 1811) with descriptions of two new species. Syst Parasitol 1 (1): 25-42. DOI: 10.1007/BF00009593.

Sabu L, Lakshmanan B, Devada K, Kumar PS. 2015. Occurrence of human sparganosis in Kerala. J Parasit Dis 39 (4): 777-779. DOI: 10.1007/s12639-014-0421-y.

Sazmand A, Miadfar MP, Deak G, Babaei M, Mendoza-Roldán JA, Otranto D. 2024. Parasites of reptiles in Iran (1922-2023): A literature review. Intl J Parasitol Parasites Wildl 25: 100992. DOI: 10.1016/j.ijppaw.2024.100992.

Schad GA. 1962. Studies on the genus *Kalicephalus* (Nematoda: Diaphanocephalidae). II. A taxonomic revision of the genus *Kalicephalus* Molin, 1861. Can J Zool 40 (6): 1035-1165. DOI: 10.1139/z62-090.

Schmidt GD, Kuntz RE. 1966. *Sphaerechinorhynchus serpenticola* sp. n. (Acanthocephala: Sphaerechinorhynchinae), a parasite of the Asian cobra *Naja naja* (Cantor) in Borneo (Malaysia). J Parasitol 52 (5): 913-916. DOI: 10.2307/3276532.

Šlapeta J, Modrý D, Johnson R. 2017. Reptile parasitology in health and disease. In: Doneley B, Monks D, Johnson R, Carmel B (eds). Reptile Medicine and Surgery in Clinical Practice. Wiley-Blackwell, Hoboken. DOI: 10.1002/9781118977705.ch31.

Stacy BA. 2020. Reptile Necropsy Techniques. In: Jacobson ER, Garner MM (eds). Infectious Diseases and Pathology of Reptiles 2nd eds. CRC Press, Boca Raton.

Tappe D, Büttner DW. 2009. Diagnosis of human visceral pentastomiasis. PLoS Negl Trop Dis 3 (2): e320. DOI: 10.1371/journal.pntd.0000320.

Utama SE, Santosa Y, Masy'ud B. 2024. The supply chain of Javan spitting cobra (*Naja sputatrix*) utilization in cobra satay businesses in Jakarta, Indonesia. Biodiversitas 25 (5): 2086-2092. DOI: 10.13057/biodiv/d250526.

Vasaruchapong T, Laoungbua P, Tawan T, Chanhome L. 2017. The survey of internal parasites of consumed Siamese cobra (*Naja kaouthia*) in Thailand. Vet Parasitol Reg Stud Rep 9: 88-92. DOI: 10.1016/j.vprsr.2017.06.005.

Verocai GG, Harvey TV, Sobotyk C, Siu RE, Kulpa M, Connolly M. 2023. *Spirometra* infection in a captive Samar cobra (*Naja samarensis*) in the United States: An imported case? Intl J Parasitol: Parasit Wildl 20: 133-137. DOI: 10.1016/j.ijppaw.2023.02.001.

Wiwanitkit V. 2005. A review of human sparganosis in Thailand. Intl J Infect Dis 9 (6): 312-316. DOI: 10.1016/j.ijid.2004.08.003.

Wolf D, Vrhovec MG, Failing K, Rossier C, Hermosilla C, Pantchev N. 2014. Diagnosis of gastrointestinal parasites in reptiles: Comparison of two coprological methods. Acta Vet Scand 56 (1): 44. DOI: 10.1186/s13028-014-0044-4.

Yao MH, Wu F, Tang LF. 2008. Human pentastomiasis in China: Case report and literature review. J Parasitol 94 (6): 1295-1298. DOI: 10.1645/ge-1597.1.

Yudhana A, Praja RN, Wardhana DK, Yunita MN, Fikri F, Fransiska EM, Ismail WA. 2020. Public health relevance of sparganosis in Javan spitting cobra (*Naja sputatrix*): A neglected zoonotic disease in Indonesia. Indian J Public Health Res Dev 11 (3): 2269-2273.

Table S1. Detailed parasitic profiles of wild-caught *Naja sputatrix* from Sidoarjo, East Java, Indonesia, based on body length, parasitological examination, and type of infection

Age of snake		**Parasite examination**			**Type of infection**
		Necropsy	**Fecal screening**	**Blood smear**	
Hatchling (<40 cm)					
1	39 cm	SPR, KLC,	KLC, STG,	-	Mixed
2	38 cm	SPR, SRC,	-	HPT	Mixed
3	40 cm	-	-	-	Negative
4	39 cm	SPR, PRP, OPD,	-	-	Mixed
Juvenile (40-80 cm)					
5	75 cm	SPR,	STG, CPL,	HPT	Mixed
6	77 cm	SPR, SRC,	STG, EMR,	-	Mixed
7	65 cm	-	-	-	Negative
8	78 cm	SRC, PRP, KLC	STG,	HPT	Mixed
9	79 cm	SPR, PRP, KLC	-	HPT	Mixed
10	67 cm	SPR,	EMR,	-	Mixed
11	79 cm	-	-	-	Negative
12	79 cm	-	-	-	Negative
13	70 cm	SPR, KLC, OPD,	CPL, EMR,	-	Mixed
14	70 cm	-	-	-	Negative
15	69 cm	SPR, SRC, KLC,	-	HPT	Mixed
16	72.5 cm	SPR,	BLT,	-	Mixed
Adult (>80 cm)					
17	147 cm	SPR, SRC, KLC	CPL	-	Mixed
18	145 cm	SPR, SRC	STG	-	Mixed
19	145 cm	-	-	-	Negative
20	107 cm	-	-	-	Negative
21	108 cm	SPR, SRC	STG	-	Mixed
22	110 cm	KLC,	-	-	Single
23	141.5 cm	SPR, SRC	-	HPT	Mixed
24	124 cm	KLC	-	-	Single
25	119 cm	-	STG	HPT	Mixed
26	135 cm	SPR, SRC	-	-	Mixed
27	94 cm	SRC	STG	-	Mixed
28	125 cm	SRC	-	-	Single
29	115 cm	-	STG	-	Single
30	110 cm	SPR, SRC, KLC	KLC	-	Mixed
31	90 cm	-	-	-	Negative
32	138 cm	SPR, SRC	EMR	-	Mixed
33	145.5 cm	SPR, SRC		HPT	Mixed
34	132 cm	-	-	HPT	Single
35	90 cm	SRC, PRP, KLC	STG	-	Mixed
36	160 cm	SPR, SRC	STG	-	Mixed
37	130 cm	SPR, PRP	CPL	HPT	Mixed
38	95 cm	SPR, SRC	-	HPT	Mixed
39	115 cm	SPR, SRC, KLC	-	-	Mixed
40	120 cm	SPR, KLC, OPD	AGC, STG	-	Mixed
41	135.5 cm	SPR, SRC, PRP	-	-	Mixed
42	145 cm	SPR,	-	HPT	Mixed
43	105 cm	SPR, SRC	CPL	HPT	Mixed
44	108 cm	OPD	OPD	-	Mixed
45	115 cm	SRC, KLC	EMR	-	Mixed
46	122 cm	KLC	-	-	Single
47	138 cm	KLC	KLC	-	Mixed
48	142 cm	-	-	-	Negative
49	150 cm	SPR, SRC	STG	HPT	Mixed
50	155 cm	SPR, SRC, KLC	-	-	Mixed
51	157 cm	SRC, KLC	EMR	HPT	Mixed

Note: SPR: *Spirometra* spp., SRC: *Sphaerechinorhynchus* spp., KLC: *Kalicephalus* spp., STG: *Strongyloides* spp., CPL: *Capillaria* spp., EMR: *Eimeria* spp., OPD: *Ophidascaris* spp., BLT: *Balantidium* spp., HPT: *Hepatozoon* spp.